



PATIENT

Sven Fox

SPECIES

Feline

BREED

DSH

SEX

MN

AGE

11Y

WEIGHT

9kg

INTERPRETED BY

Dr. Leticia Utsch MV

IMAGING PERFORMED BY

CS & KP

HOSPITAL NAME

My Pet Mobile Vet

REFERRING VET

Dr. Celestine Hoh

INVOICE

75059

DATE

5-19-26

PRESENTING CLINICAL SIGNS

Not wanting to put weight on hind right leg on 5/14/26. Has since improved, but P still being careful with limb.

Abnormal PE/Chem/CBC/UA Results: No limping or pain when flexing upon examination. Suspected pulled muscle, thickened right knee. Solensia and acupuncture performed at time of imaging. BCS 8/9.

RADIOGRAPHIC STUDY OF THE PELVIS AND STIFLES

Radiographs of the pelvis and stifles in three imaging planes are provided for review.

RADIOGRAPHIC FINDINGS

Narrowing of the L7-S1 intervertebral disc space with mild endplate sclerosis and ventral spondylosis is seen.

The hips and stifle joints are congruent.

The patellae appear laterally displaced due to positioning.

No signs of degenerative joint disease seen.

The soft tissues appear normal.

RADIOGRAPHIC DIAGNOSIS

- L7-S1 changes are concerning for lumbosacral degenerative stenosis.

INTERPRETATION OF FINDINGS & FURTHER RECOMMENDATIONS

Lumbosacral changes observed may be contributing to the clinical signs (neurologic pain or nerve root irritation secondary to lumbosacral disease). Correlation with neurologic and orthopedic examination findings is recommended. Conservative management, including weight reduction, multimodal analgesia and rehabilitation therapies may be appropriate initially. Continued adjunctive therapies such as Solensia and acupuncture may also be beneficial. Advanced imaging (CT/MRI) may be beneficial if clinical signs persist, progress, or neurologic deficits develop.



PATIENT

Sven Fox

SPECIES

Feline

BREED

DSH

SEX

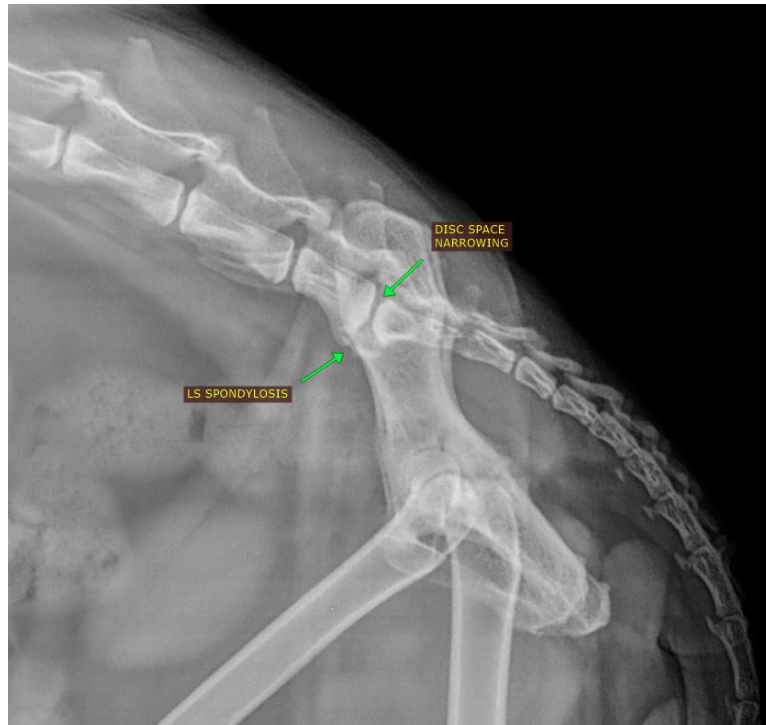
MN

AGE

11Y

WEIGHT

9kg



INTERPRETED BY

Dr. Leticia Utsch MV

IMAGING PERFORMED BY

CS & KP

HOSPITAL NAME

My Pet Mobile Vet

REFERRING VET

Dr. Celestine Hoh

INVOICE

75059

DATE

5-19-26

The information and recommendations provided are based on the images presented by the referring veterinarian. No evaluation can be communicated regarding pathology that was not visible in the image/video clips provided.

Thank you for this referral. If the clinical or image interpretation does not parallel your findings or if I can be of any further assistance please contact me.

Dr. Leticia Utsch MV

info@sonopath.com