



## PATIENT

Baby Lamoureux

## SPECIES

Canine

## BREED

Chihuahua

## SEX

Female Spayed

## AGE

12Y

## WEIGHT

2.1kg

## INTERPRETED BY

Dr. Leticia Utsch MV

## IMAGING PERFORMED BY

GDD

## HOSPITAL NAME

Green Dog Dental and Wellness

## REFERRING VET

Dr. Hoh

## INVOICE

75026

## DATE

5-18-26

## PRESENTING CLINICAL SIGNS

Baby Lamoureux presents for coughing episode that kept client awake until 1 AM last night. Known tracheal collapse

Currently on heart medication

Coughing triggered by excitement

Choking on water

Previously prescribed trazodone and gabapentin (liquid formulations)

History of heart disease

Had echocardiogram last year without chest radiographs

## RADIOGRAPHIC STUDY OF THE THORAX

Radiographs of the thorax in three imaging planes are provided for review.

## RADIOGRAPHIC FINDINGS

The tracheal diameter in the cervicothoracic region is severely reduced.

The principal bronchi appear normal.

The heart is normal appearing and there is no evidence of left atrial dilation. Pulmonary vasculature appears normal.

The lungs are normal transparent.

The mediastinum and pleural space appear normal.

Bone structures are unremarkable.

In the partially included abdomen, millimetric mineral opacities are seen in the stomach fundus, likely incidental foreign bodies.

## RADIOGRAPHIC DIAGNOSIS

- Severe cervicothoracic tracheal collapse.

## INTERPRETATION OF FINDINGS & FURTHER RECOMMENDATIONS

The severe tracheal collapse is likely accounted for the reported coughing episodes and respiratory distress. Medical management is clinically indicated and may include antitussive therapy (e.g. butorphanol), anxiolytic/sedative therapy when appropriate (e.g. trazodone), and anti-inflammatory therapy as clinically indicated. Weight management, environmental modification, and avoidance of respiratory irritants or excitement are recommended. If clinical signs worsen or become refractory to medical management, consider tracheobronchoscopy for further assessment of dynamic airway collapse and potential interventional options.



## PATIENT

Baby Lamoureux

## SPECIES

Canine

## BREED

Chihuahua

## SEX

Female Spayed

## AGE

12Y

## WEIGHT

2.1kg

## INTERPRETED BY

Dr. Leticia Utsch MV

## IMAGING PERFORMED BY

GDD

## HOSPITAL NAME

Green Dog Dental and Wellness

## REFERRING VET

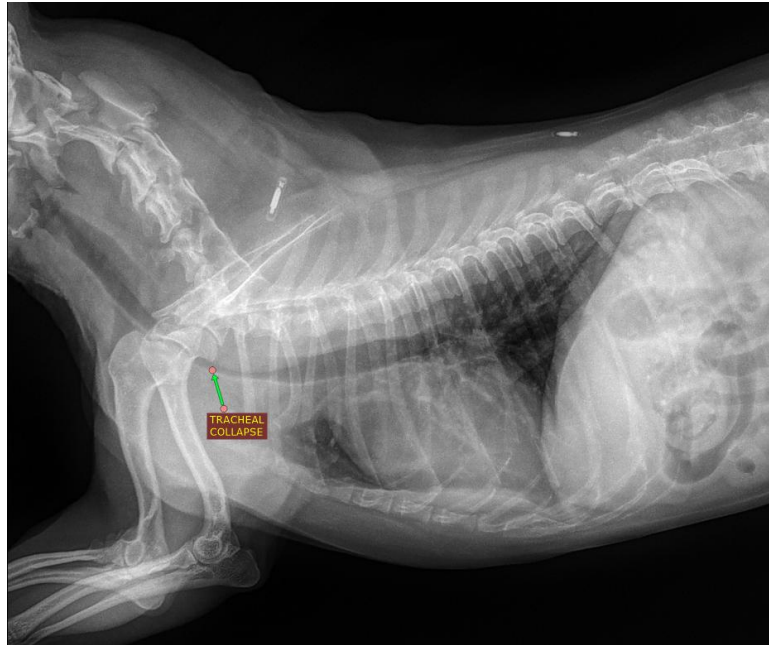
Dr. Hoh

## INVOICE

75026

## DATE

5-18-26



The information and recommendations provided are based on the images presented by the referring veterinarian. No evaluation can be communicated regarding pathology that was not visible in the image/video clips provided.

Thank you for this referral. If the clinical or image interpretation does not parallel your findings or if I can be of any further assistance please contact me.

**Dr. Leticia Utsch MV**

[info@sonopath.com](mailto:info@sonopath.com)