



## PATIENT

Huwt Dymond

## SPECIES

Canine

## BREED

Belgian Malinois

## SEX

Intact Male

## AGE

5 Years

## WEIGHT

64 lbs

## INTERPRETED BY

Dr. Leticia Utsch MV

## IMAGING PERFORMED BY

John Bucha VMD

## HOSPITAL NAME

Harevys Lake  
Veterinary Clinic

## REFERRING VET

John Bucha VMD

## INVOICE

16303

## DATE

05/15/26

## PRESENTING CLINICAL SIGNS

Owner wanted radiographs sent out for OFA certification.

Abnormal PE/Chem/CBC/UA Results: CBC , CHEM 17 ( all within normal limits) 4dx ( anaplasma + since 2022)

## RADIOGRAPHIC STUDY OF THE PELVIS, ELBOWS AND TARSI

Radiographs of the pelvis and elbows in one imaging plane and radiographs of the tarsi in two image planes are provided for review.

## RADIOGRAPHIC FINDINGS

### Pelvis

The hip joints are congruent.  
No evidence of degenerative joint disease.  
The pelvic bones appear normal.  
The patellae are laterally displaced due to positioning.  
The soft tissues have normal thickness.

### Elbows

The hip joints are congruent.  
No evidence of degenerative joint disease.  
No evidence of NUPA.  
The soft tissues have normal thickness.

### Tarsi

The tarsi joints are congruent.  
The digits appear normal.  
No evidence of degenerative joint disease.  
The soft tissues have normal thickness.

## RADIOGRAPHIC DIAGNOSIS

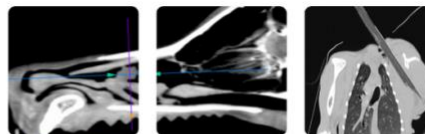
- Normal appearing hips, elbows and tarsi.

## INTERPRETATION OF FINDINGS & FURTHER RECOMMENDATIONS

No radiographic evidence of hip or elbow dysplasia is identified on the current study. The tarsal joints are also normal. These findings are favorable from an orthopedic standpoint. It is important to note that radiographic screening does not completely exclude joint laxity. Recommend correlate to orthopedic examination.

**The information and recommendations provided are based on the images presented by the referring veterinarian. No evaluation can be communicated regarding pathology that was not visible in the image/video clips provided.**

Thank you for this referral. If the clinical or image interpretation does not parallel your findings or if I can be of any further assistance please contact me.



## PATIENT

Huwt Dymond

## SPECIES

Canine

## BREED

Belgian Malinois

## SEX

Intact Male

## AGE

5 Years

## WEIGHT

64 lbs

## INTERPRETED BY

Dr. Leticia Utsch MV

## IMAGING PERFORMED BY

John Bucha VMD

## HOSPITAL NAME

Harevys Lake  
Veterinary Clinic

## REFERRING VET

John Bucha VMD

## INVOICE

16303

## DATE

05/15/26

**Dr. Leticia Utsch MV**

[info@sonopath.com](mailto:info@sonopath.com)