



PATIENT

Brutus Bisch

SPECIES

Canine

BREED

Great Pyreneese Mix

SEX

Neutered Male

AGE

10 Years

WEIGHT

85.3

INTERPRETED BY

Dr. Leticia Utsch MV

IMAGING PERFORMED BY

GC/JR

HOSPITAL NAME

The Pet Hospital of Stratford

REFERRING VET

Dr. Claudia Giuliani DVM

INVOICE

16268

DATE

05/15/26

PRESENTING CLINICAL SIGNS

Brutus presents for concerns of growth on L carpus that mom noticed about a year ago. Has grown since first noticing. Not bothering him. ~6 cm growth around L carpus.

RADIOGRAPHIC STUDY OF THE DISTAL FORELIMBS

Radiographs of the distal forelimbs in two imaging planes are provided for review.

RADIOGRAPHIC FINDINGS

Moderately-defined soft tissue mass seen in the left distal forelimb. The mass appears to be two coalescing nodules and it measures approximately 11.6 cm length and 7.0 cm wide in total.

There is no evidence of secondary bone lyses or periosteal reaction.

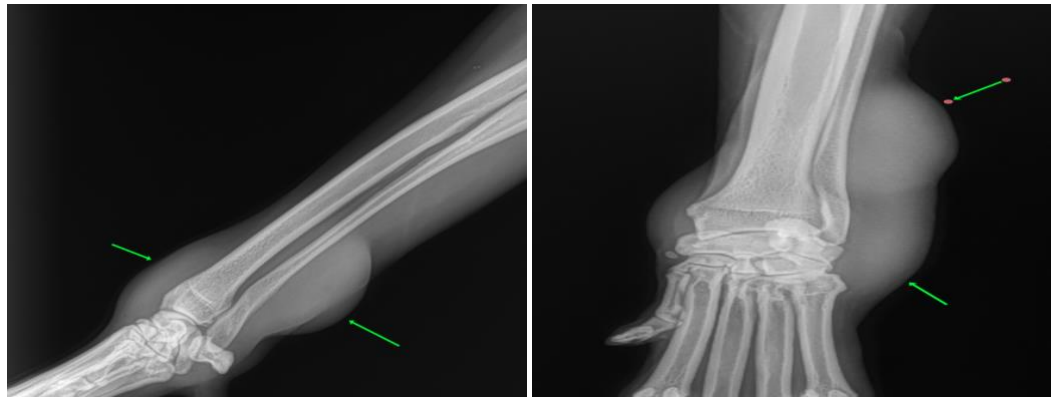
The carpus and elbow joints appear congruent. No degenerative joint disease seen.

RADIOGRAPHIC DIAGNOSIS

- Soft tissue mass with no bone involvement in distal left forelimb.

INTERPRETATION OF FINDINGS & FURTHER RECOMMENDATIONS

The large soft tissue mass seen in the left limb is concerning for a soft tissue neoplasm, especially given the reported growth noted by the owner, such as mass cell tumor or soft tissue sarcoma. Correlation with cytology and/or histopathology is recommended for definitive diagnosis



The information and recommendations provided are based on the images presented by the referring veterinarian. No evaluation can be communicated regarding pathology that was not visible in the image/video clips provided.

Thank you for this referral. If the clinical or image interpretation does not parallel your findings or if I can be of any further assistance please contact me.

Dr. Leticia Utsch MV

info@sonopath.com