

PATIENT

AppleJack Colm

SPECIES

Canine

BREED

Airedale

SEX

Neutered male

AGE

10 years

WEIGHT

68 lbs

INTERPRETED BY

Dr. Lawrence McGill,
 DVM,Ph.D.,Diplomate,
 ACVP

IMAGING PERFORMED BY

Rebecca Hamilton

HOSPITAL NAME

Allendale VH

REFERRING VET

Dr. Tartini

INVOICE

78285

DATE

6/2/26

PRESENTING CLINICAL SIGNS

History: R anal gland nodule. met check of abdomen.
 Abnormal PE/Chem/CBC/UA Results: HCT 50%, Plat 302K, Normal Calcium 10.0, mildly ^ Chol 332

CYTOLOGY SUBMISSION

FNA of the liver was submitted

OBSERVATIONS

Liver: Submitted are 13 excellent videos and 2 images of cells collected from the liver in AppleJack. The majority of the collection consists of a background of red blood cells interspersed with a mixture of inflammatory cells including neutrophils and lymphocytes. There are rare aggregates of hepatocytes. These hepatocytes demonstrate slight granularity and vacuolization. There is no suggestion of malignancy. Atypical epithelial cells are not identified.

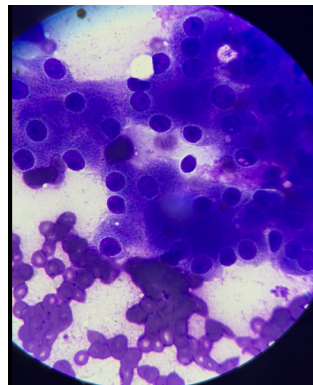
INTERPRETATION OF FINDINGS & FURTHER RECOMMENDATIONS

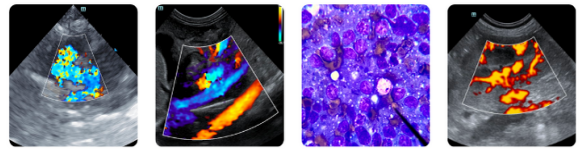
Liver - Consistent with mild suppurative hepatitis and possible nodular hyperplasia.

COMMENTS

The cellularity in this collection included very few have hepatocellular aggregates. The majority of the collection consists of hemorrhage with inflammatory change. There is no suggestion of malignancy or sepsis. Nodular hyperplasia easily could be a part of these nodules in the liver. Excision biopsy will be required to confirm the underlying process which likely will be benign. Very likely the cellular changes in this collection are secondary and not primary. A guarded prognosis is warranted since the underlying process has not been identified.

CYTOLOGY IMAGE





PATIENT

AppleJack Colm

This is an image of a group of hepatocytes which are few in numbers in this collection from AppleJack. There is moderate inflammation in the other images.

SPECIES

Canine

The information and recommendations provided are based on the images presented by the referring veterinarian/sonographer. No evaluation can be communicated regarding pathology that was not visible in the image/video clips provided.

BREED

Airedale

Thank you for this referral. If the clinical or image interpretation does not parallel your findings or if I can be of any further assistance please contact me.

SEX

Neutered male

L.D. McGill, DVM, Ph.D., DACVP

AGE

10 years

8288 Top of the World Dr. Cottonwood Heights, UT 84121

Cell: 801-865-1220 Ldmcgill.vetpath@gmail.com

WEIGHT

68 lbs

INTERPRETED BY

Dr. Lawrence McGill,
DVM,Ph.D.,Diplomate,
ACVP

**IMAGING
PERFORMED BY**

Rebecca Hamilton

HOSPITAL NAME

Allendale VH

REFERRING VET

Dr. Tartini

INVOICE

78285

DATE

6/2/26