

PATIENT

Benny Bove

SPECIES

Feline

BREED

SEX

Neutered male

AGE

15 years

WEIGHT

Not provided.

INTERPRETED BY

Dr. Lawrence McGill,
DVM,Ph.D.,Diplomate,
ACVP

**IMAGING
PERFORMED BY**

Vincent Ravancho

HOSPITAL NAME

The Gentle Vet

REFERRING VET

Dr. Gwiazdowski

INVOICE

78044

DATE

5/27/26

PRESENTING CLINICAL SIGNS

History: FNA of the liver
Abnormal PE/Chem/CBC/UA Results: vacuolar hepatopathy

CYTOLOGY SUBMISSION

FNA of the liver was submitted

OBSERVATIONS

Liver: Submitted are 4 excellent videos of moderate to excellent collections of cells from the liver in Benny. The cellularity consists of good collections of hepatocytes many of which are vacuolated. The vacuoles appear to be quite large and support lipid. There are scattered neutrophils associated with the hepatocytes and in the surrounding red blood cells. Lymphocytes are few. There is no suggestion of malignancy in the collection.

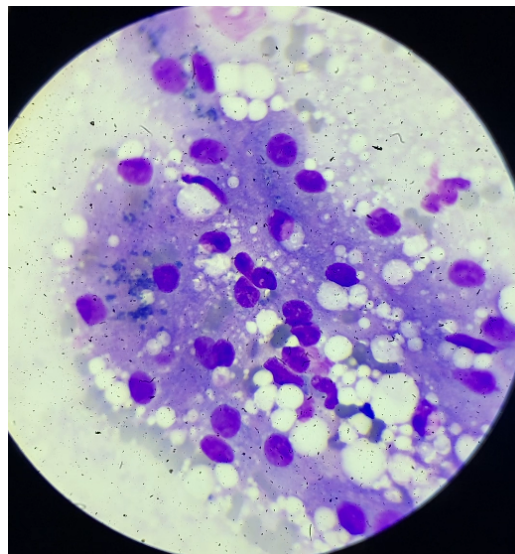
INTERPRETATION OF FINDINGS & FURTHER RECOMMENDATIONS

Liver - Hepatocellular vacuolization consistent with lipidosis and feline fatty liver syndrome and mild suppurative hepatitis.

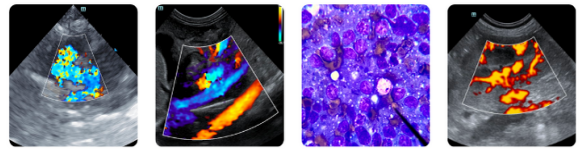
COMMENTS

The cellularity in this collection strongly suggests the likelihood of very early feline fatty liver syndrome. There is inflammation in the liver which easily could be secondary to inflammation in other organs in the abdominal cavity. The liver changes are likely secondary. I would be concerned about the possibility of pancreatitis or enteritis in Benny. A guarded prognosis is warranted since these changes are likely secondary and the primary process is not present in these collections.

CYTOLOGY IMAGE



This is an image of hepatocytes collected from Benny. Note the vacuoles and prominent lipid collected in this field. Other fields had lipid in the background as well.



PATIENT

Benny Bove

SPECIES

Feline

BREED

The information and recommendations provided are based on the images presented by the referring veterinarian/sonographer. No evaluation can be communicated regarding pathology that was not visible in the image/video clips provided.

SEX

Neutered male

Thank you for this referral. If the clinical or image interpretation does not parallel your findings or if I can be of any further assistance please contact me.

L.D. McGill, DVM, Ph.D., DACVP

AGE

15 years

8288 Top of the World Dr. Cottonwood Heights, UT 84121

Cell: 801-865-1220 Ldmcgill.vetpath@gmail.com

WEIGHT

Not provided.

INTERPRETED BY

Dr. Lawrence McGill,
DVM,Ph.D.,Diplomate,
ACVP

**IMAGING
PERFORMED BY**

Vincent Ravancho

HOSPITAL NAME

The Gentle Vet

REFERRING VET

Dr. Gwiazdowski

INVOICE

78044

DATE

5/27/26