

**PATIENT**

Sage Klinger

**SPECIES**

Canine

**BREED**

Terrier Mix

**SEX**

Spayed female

**AGE**

13 years

**WEIGHT**

32 lbs

**INTERPRETED BY**

Dr. Lawrence McGill,  
DVM,Ph.D.,Diplomate,  
ACVP

**IMAGING PERFORMED BY**

Meghan Morse, LVT,  
CVT

**HOSPITAL NAME**

Walden AC

**REFERRING VET**

Dr. Dickey

**INVOICE**

72283

**DATE**

2/6/26

**PRESENTING CLINICAL SIGNS**

- Large hepatic cyst seen on AUS. AUS performed due to complaints of acute v+ and lethargy.
- Cyst aspirated with 25G gauge needle/ 3cc syringe and slides prepared from both whole sample and sediment samples.
- Fluid color clear upon aspiration.

**OBSERVATIONS**

Hepatic cyst: Submitted is an excellent video of noncellular fluid collected from the hepatic cyst in Sage. There are no cells in the video. There is clear fluid demonstrated in the tube. This suggests a noncellular cystic process in the liver.


**INTERPRETATION OF FINDINGS & FURTHER RECOMMENDATIONS**

Hepatic cyst - Noncellular fluid.

**COMMENTS**

With no cells to evaluate in the cystic fluid, we are unable to identify the specific source of this cyst. It could be from any location in the liver. It certainly is benign since there are no cells present. It could be surrounded by granulation tissue, or an unusual bile duct cyst with clear fluid not bile. A guarded prognosis is warranted since the specific source of the cyst has not been confirmed.

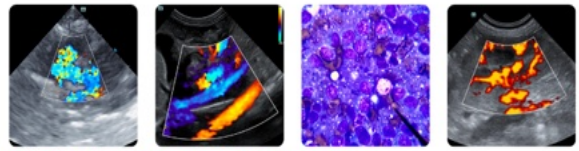
**CYTOLOGY IMAGE**



This is an image that demonstrates a field of clear fluid smear with no cells present collected from the hepatic cyst in Sage.

**The information and recommendations provided are based on the images presented by the referring veterinarian/sonographer. No evaluation can be communicated regarding pathology that was not visible in the image/video clips provided.**

Thank you for this referral. If the clinical or image interpretation does not parallel your findings or if I can be of any further assistance please contact me.



**PATIENT**

**L.D. McGill, DVM, Ph.D., DACVP**

Sage Klinger

8288 Top of the World Dr. Cottonwood Heights, UT 84121

**SPECIES**

Cell: 801-865-1220 [Ldmcgill.vetpath@gmail.com](mailto:Ldmcgill.vetpath@gmail.com)

Canine

**BREED**

Terrier Mix

**SEX**

Spayed female

**AGE**

13 years

**WEIGHT**

32 lbs

**INTERPRETED BY**

Dr. Lawrence McGill,  
DVM, Ph.D., Diplomate,  
ACVP

**IMAGING  
PERFORMED BY**

Meghan Morse, LVT,  
CVT

**HOSPITAL NAME**

Walden AC

**REFERRING VET**

Dr. Dickey

**INVOICE**

72283

**DATE**

2/6/26