New Jersey Mobile
FUELED BY SONOPATH VETERINARY ULTRASOUND

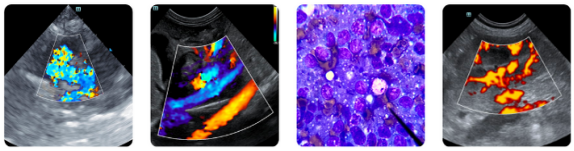

Clinical Sonography & Telecytology
Educational Teleconsultation Services™

SonoPath FOSTERING THE ART OF VETERINARY MEDICINE™
www.SonoPath.com
info@sonopath.com 800.838.4268

PATIENT
Odin Bisconti

SPECIES
Feline

BREED
Domestic Longhair

SEX
Neutered male

AGE
11 years

WEIGHT
15.1 lbs

INTERPRETED BY
Dr. Lawrence McGill, DVM,Ph.D.,Diplomate, ACVP

IMAGING PERFORMED BY
Kerri Becker

HOSPITAL NAME
Animal Care Center of Flanders

REFERRING VET
Dr. Hallihan

INVOICE
69224

DATE
12/2/25

PRESENTING CLINICAL SIGNS

History: FNA liver, pancreatic mass previously
Abnormal PE/Chem/CBC/UA Results: PLT Count (>80k): 270 HCT (>20%) : 48.9%

CYTOLOGY SUBMISSION

FNA of the liver was submitted

OBSERVATIONS

Liver: Submitted are 3 excellent videos of hemodiluted collection including inflammatory cells but no hepatocytes collected from the liver in Odin. The nucleated cells present in the collection are mainly neutrophils with scattered lymphocytes and rare macrophages. Again hepatocytes were not identified. This is essentially a blood collection from the liver.

INTERPRETATION OF FINDINGS & FURTHER RECOMMENDATIOINS

Liver - Hemodiluted collection with evidence of neutrophilic inflammation and no other changes.

COMMENTS

There were no hepatocytes in the collection that I could identify. There are aggregates of platelets which support an acute hemorrhagic collection. The neutrophils suggest some type of neutrophilic or inflammatory response. The hepatocytes could be vacuolated or even changes supporting lipidosis but I was unable to make that determination. With the inflammatory process present, I would be concerned about the possibility of pancreatitis or other causes for inflammation associated with the liver. Malignancy is not suggested in this collection.

New Jersey Mobile
FUELED BY SONOPATH VETERINARY ULTRASOUND

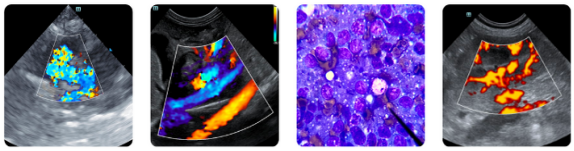

Clinical Sonography & Telecytology
Educational Teleconsultation Services™

SonoPath
FOSTERING THE ART OF VETERINARY MEDICINE™
www.SonoPath.com
info@sonopath.com 800.838.4268

PATIENT

Odin Bisconti

SPECIES

Feline

BREED

Domestic Longhair

SEX

Neutered male

AGE

11 years

WEIGHT

15.1 lbs

INTERPRETED BY

Dr. Lawrence McGill, DVM,Ph.D.,Diplomate, ACVP

IMAGING PERFORMED BY

Kerri Becker

HOSPITAL NAME

Animal Care Center of Flanders

REFERRING VET

Dr. Hallihan

INVOICE

69224

DATE

12/2/25

CYTOLOGY IMAGE

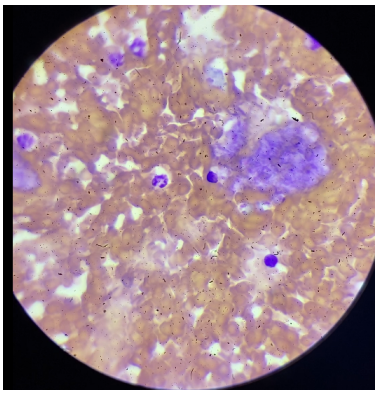

This is an image of a representative area of hemodiluted sample collected from the liver in Odin. There are neutrophils with lymphocytes and aggregates of platelets in this collection besides the red blood cells.

The information and recommendations provided are based on the images presented by the referring veterinarian/sonographer. No evaluation can be communicated regarding pathology that was not visible in the image/video clips provided.

Thank you for this referral. If the clinical or image interpretation does not parallel your findings or if I can be of any further assistance please contact me.

L.D. McGill, DVM, Ph.D., DACVP

8288 Top of the World Dr. Cottonwood Heights, UT 84121

Cell: 801-865-1220 Ldmcgill.vetpath@gmail.com