

PATIENT

Gazelle Peck

SPECIES

Canine

BREED

Miniature Pinscher

SEX

Spayed female

AGE

13 years

WEIGHT

12.5 lbs

INTERPRETED BY

Dr. Lawrence McGill,
DVM, Ph.D., Diplomate,
ACVP

IMAGING PERFORMED BY

Sara Hansen

HOSPITAL NAME

Ark AH

REFERRING VET

Dr. Guy

INVOICE

74859

DATE

4/27/26

PRESENTING CLINICAL SIGNS

History: Bilateral cataracts, Moderate dental tartar, Chronic hepatopathy, Eating/Drinking/Urinating/Defecating normally

ABNORMAL Labwork Values
04/15/26 03/09/26 03/19/25 03/18/23

Globulin 3.9 (1.6-3.6) H 3.9
AST 140 (15-66) H 71

ALT 570 (12-118) H 581 467 842
ALP 786 (5-131) H 362 569 374

GGT 19 (1-12) H 22 19 23
03/09/26

RBC 8.0 (4.8-9.3) WNL 8.0
nRBC 5 (0-1) 6

platelet 100 (with small clumps) 102

Current Medications

Denamarin Advanced started 03/12/26, no improvement

CYTOLOGY SUBMISSION

FNA of the liver and spleen were submitted

OBSERVATIONS

Liver: Submitted are 2 good videos of cells collected from the liver in gazelle. The hepatocytes demonstrate slight granularity of the cytoplasm. The samples are hemodiluted with scattered inflammatory cells. There is no suggestion of any specific pathology or neoplasia in the collection.

Spleen: Submitted are 2 good videos of cells collected from the spleen. The samples are hemodiluted. There are aggregates of cells that have the appearance of histiocytic cells or macrophages. There are scattered inflammatory cells. The cellularity is minimal in the splenic collection except for the aggregates of apparent histiocytic cells.

INTERPRETATION OF FINDINGS & FURTHER RECOMMENDATIONS

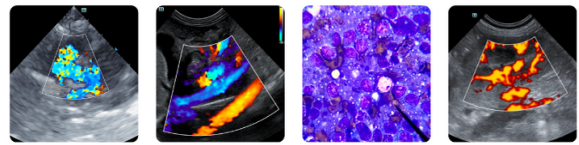
Liver - Relatively normal hepatocytes with no evidence of neoplasia or primary inflammation.

Spleen - Aggregates of histiocytic cells with no evidence of primary inflammation.

COMMENTS

The liver changes are not specific and suggest the possibility of weak hepatocellular membranes. This could be secondary to many different conditions and is no suggestion of primary inflammation or change. There is a possibility that the hepatocytes are weakening membranes and nonspecific with respect to any pathology. This change may be due to hepatocellular aging.

The spleen supports some histiocytic changes. The cause for the histiocytic changes are not identified. Splenectomy may be required to confirm that process. Histiocytic changes are possible in many different processes in the dog. A guarded prognosis is warranted since an underlying process has not been identified.



PATIENT

Gazelle Peck

SPECIES

Canine

BREED

Miniature Pinscher

SEX

Spayed female

AGE

13 years

WEIGHT

12.5 lbs

INTERPRETED BY

Dr. Lawrence McGill,
DVM, Ph.D., Diplomate,
ACVP

IMAGING PERFORMED BY

Sara Hansen

HOSPITAL NAME

Ark AH

REFERRING VET

Dr. Guy

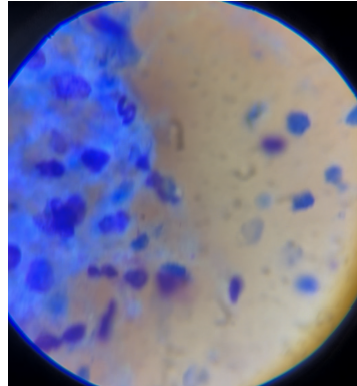
INVOICE

74859

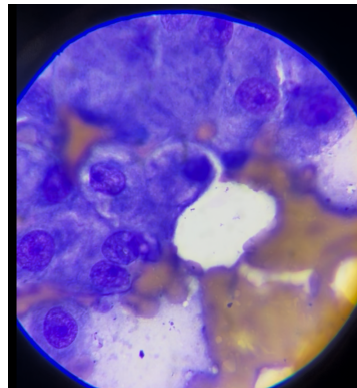
DATE

4/27/26

CYTOLOGY IMAGE



This is an image of some of the cells collected from the spleen. The image is slightly out of focus as are many of the videos in the collection from the spleen in Gazelle.



This is an image of the hepatocytes collected from the liver in Gazelle. Note the granularity to the cytoplasm and slight vacuolization of these hepatocytes. No other changes are identified.

The information and recommendations provided are based on the images presented by the referring veterinarian/sonographer. No evaluation can be communicated regarding pathology that was not visible in the image/video clips provided.

Thank you for this referral. If the clinical or image interpretation does not parallel your findings or if I can be of any further assistance please contact me.

L.D. McGill, DVM, Ph.D., DACVP
8288 Top of the World Dr. Cottonwood Heights, UT 84121
Cell: 801-865-1220 Ldmcgill.vetpath@gmail.com