

PATIENT

James DiMiceli

SPECIES

Feline

BREED

Domestic Shorthair

SEX

Neutered male

AGE

7 years

WEIGHT

8.5 lbs

INTERPRETED BY

Dr. Lawrence McGill,
DVM, Ph.D., Diplomate,
ACVP

IMAGING PERFORMED BY

Sara Hansen

HOSPITAL NAME

Q Street AH

REFERRING VET

Dr. Bretschneider

INVOICE

74099

DATE

4/2/26

PRESENTING CLINICAL SIGNS

- Clinical Exam Findings: Weight loss, chronic intermittent vomiting, approx 2 inch mass palpable central abdomen
- ABNORMAL Labwork Values: low normal HCT = 31.8, Albumin 2.4, Total Protein 5.3, ALT 10, ALP 6, Reticulocytes 87. Otherwise normal
- Current Medications Ondasetron as needed for anti-nausea effects

CYTOLOGY SUBMISSION

FNA of the abdominal mass was submitted.

OBSERVATIONS

Abdominal mass: Submitted are 2 excellent videos of hemodiluted collections of nucleated cells from the abdominal mass in James. The nucleated cellularity consists of 90% neutrophils with scattered lymphoid cells. The majority of the collection consists of red blood cells. There are large aggregates of platelets throughout the collection. Malignant changes are not suggested.

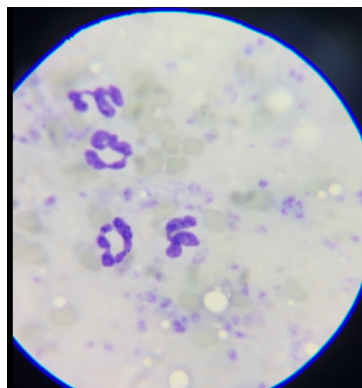
INTERPRETATION OF FINDINGS & FURTHER RECOMMENDATIONS

Abdominal mass - Hemodiluted sample with suppurative inflammation.

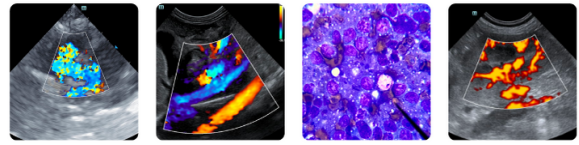
COMMENTS

The collection from this site demonstrates large numbers of neutrophils with rare lymphocytes. This supports a suppurative inflammatory response. This could be within the lymph node or could be in a mass itself. This could be a localized inflammatory process or more than likely it is FIP. Further evaluation for feline coronavirus is encouraged. There is no suggestion of malignancy in this collection. A guarded prognosis is warranted until the underlying process can be confirmed.

CYTOLOGY IMAGE



This is an image that demonstrates neutrophils and large numbers of platelets interspersed with red blood cells collected from the abdominal mass in James. The presence of platelets suggests an acute hemorrhagic process as a result of aspiration.



PATIENT

James DiMiceli

SPECIES

Feline

BREED

Domestic Shorthair

SEX

Neutered male

AGE

7 years

WEIGHT

8.5 lbs

INTERPRETED BY

Dr. Lawrence McGill,
DVM, Ph.D., Diplomate,
ACVP

IMAGING PERFORMED BY

Sara Hansen

HOSPITAL NAME

Q Street AH

REFERRING VET

Dr. Bretschneider

INVOICE

74099

DATE

4/2/26

The information and recommendations provided are based on the images presented by the referring veterinarian/sonographer. No evaluation can be communicated regarding pathology that was not visible in the image/video clips provided.

Thank you for this referral. If the clinical or image interpretation does not parallel your findings or if I can be of any further assistance please contact me.

L.D. McGill, DVM, Ph.D., DACVP

8288 Top of the World Dr. Cottonwood Heights, UT 84121

Cell: 801-865-1220 Ldmcgill.vetpath@gmail.com