

**PATIENT**

Cali Rosa

**SPECIES**

Feline

**BREED**

Domestic Shorthair

**SEX**

Spayed female

**AGE**

13 years

**WEIGHT**

11.8 lbs

**INTERPRETED BY**

Dr. Lawrence McGill,  
DVM,Ph.D.,Diplomate,  
ACVP

**IMAGING PERFORMED BY**

Sara Hansen

**HOSPITAL NAME**

Paws AH

**REFERRING VET**

Dr. Johnson

**INVOICE**

73474

**DATE**

3/16/26

**PRESENTING CLINICAL SIGNS**

- Clinical Exam Findings: Patient presented for weight loss and mild decrease in appetite; History of Cholangiohepatitis
- ABNORMAL Labwork Values ALT >1000; ALP 148
- Current Medications Metronidazole(100mg/mL) 0.8mL PO q 12 hours x 7 days; Amoxicillin(50mg/mL) 50mg PO q 12 hours x 7 days; Inhalers for asthma

**CYTOLOGY SUBMISSION**

FNA of the spleen was submitted

**OBSERVATIONS**

Spleen: Submitted is 1 excellent video of moderate collections of nucleated cells within a hemodiluted collection of cells from the spleen in Cali. The cellularity consists of large numbers of red blood cells interspersed with nucleated cells that are mixed with neutrophils and lymphocytes. Scattered smudge cells are present. The lymphoid cells are small mature lymphocytes. Neutrophils are present in numbers similar to the lymphocytes. Malignant characteristics are not confirmed.

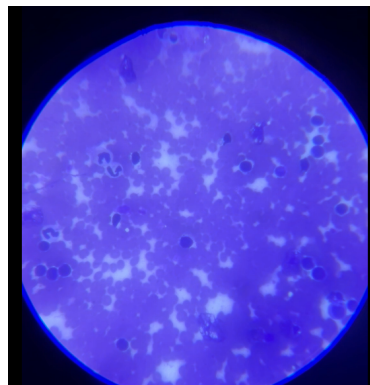
**INTERPRETATION OF FINDINGS & FURTHER RECOMMENDATIONS**

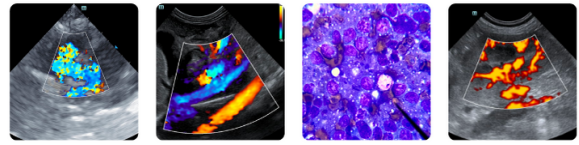
Spleen - Hemodiluted collection with apparent chronic suppurative and lymphocytic splenitis.

**COMMENTS**

The changes in the spleen suggest a congested spleen with a mixture of inflammatory cells. The inflammatory cells include neutrophils and lymphocytes. This suggests splenic inflammation and splenitis. This can be secondary to a diffuse inflammatory process in the abdominal cavity or it could also be secondary to FIP. There is no suggestion of malignancy in this collection. A guarded to unfavorable prognosis is warranted until the underlying process is identified. Very likely the changes in this spleen are secondary to problems in other locations.

**CYTOLOGY IMAGE**





**PATIENT**

Cali Rosa

This is an image demonstrating a background of red blood cells with a mixed cellular collection of neutrophils and small mature lymphocytes collecting from the spleen in Cali. Neoplasia cannot be confirmed.

**SPECIES**

Feline

**BREED**

Domestic Shorthair

**The information and recommendations provided are based on the images presented by the referring veterinarian/sonographer. No evaluation can be communicated regarding pathology that was not visible in the image/video clips provided.**

**SEX**

Spayed female

Thank you for this referral. If the clinical or image interpretation does not parallel your findings or if I can be of any further assistance please contact me.

**AGE**

13 years

**L.D. McGill, DVM, Ph.D., DACVP**

8288 Top of the World Dr. Cottonwood Heights, UT 84121

Cell: 801-865-1220 [Ldmcgill.vetpath@gmail.com](mailto:Ldmcgill.vetpath@gmail.com)

**WEIGHT**

11.8 lbs

**INTERPRETED BY**

Dr. Lawrence McGill,  
DVM, Ph.D., Diplomate,  
ACVP

**IMAGING PERFORMED BY**

Sara Hansen

**HOSPITAL NAME**

Paws AH

**REFERRING VET**

Dr. Johnson

**INVOICE**

73474

**DATE**

3/16/26