



PATIENT

Charlie Oxana

SPECIES

Canine

BREED

Golden Retriever

SEX

Neutered male

AGE

12 years

WEIGHT

37 lbs

INTERPRETED BY

Dr. Lawrence McGill,
DVM, Ph.D., Diplomate,
ACVP

IMAGING PERFORMED BY

Sheila Jepchumba

HOSPITAL NAME

Pawsitive Veterinary
Clinic Dubai Silicon
Oasis

REFERRING VET

Dr. Raza

INVOICE

78161

DATE

6/1/26

PRESENTING CLINICAL SIGNS

Charlie is a 12-year-old male neutered dog. A fine-needle aspiration (FNA) sample from a nasal mass was submitted several days ago, and cytologic evaluation by SonoPath was reported as being suspicious for carcinoma. For staging purposes, fine-needle aspiration samples have now been obtained from the left and right mandibular (submandibular) lymph nodes and are being submitted for cytologic evaluation. The purpose of this submission is to assess for potential metastatic spread of the suspected nasal neoplasm to the regional lymph nodes.

Please find the accompanying cytology images labeled as follows:

Left LN – Left submandibular lymph node

Right LN – Right submandibular lymph node

Evaluation of these samples is requested to determine whether metastatic neoplastic cells are present within either lymph node.

CYTOLOGY SUBMISSION

FNA of the left and right lymph node were submitted

OBSERVATIONS

Left Lymph node: Submitted are 33 very good images of cells collected from the left lymph node on Charlie. There are very good collections of lymphoid cells with scattered plasma cells and macrophages. Malignant cellularity and particularly epithelial cells are not identified. There is definitely some inflammation draining to this lymph node since the lymphoid tissue appears to be reactive.

Right lymph node: Submitted are 22 very good images of cells collected from the right lymph node on Charlie. There are very good collections of lymphoid cells which are irregular in size and shape supporting reactivity. Malignant characteristics are not identified in this cellularity. There are scattered macrophages that are larger. Plasma cells are observed.

INTERPRETATION OF FINDINGS & FURTHER RECOMMENDATIONS

Left lymph node - Reactive or stimulated lymph node.

Right lymph node - Reactive or stimulated lymph node.

COMMENTS

Both lymph nodes demonstrate reactive lymphoid tissue with no evidence of malignancy. There is no suggestion of epithelial cells infiltrating into either lymph node. There is some inflammation draining to the node which would be expected both from the nasal tumor and from possible gingival inflammation. Cytologically this collection appears to be a reactive node from inflammatory processes and not malignancy. A guarded prognosis is warranted.



PATIENT

Charlie Oxana

SPECIES

Canine

BREED

Golden Retriever

SEX

Neutered male

AGE

12 years

WEIGHT

37 lbs

INTERPRETED BY

Dr. Lawrence McGill,
DVM, Ph.D., Diplomate,
ACVP

IMAGING PERFORMED BY

Sheila Jepchumba

HOSPITAL NAME

Pawsitive Vetreinary
Clinic Dubai Silicon
Oasis

REFERRING VET

Dr. Raza

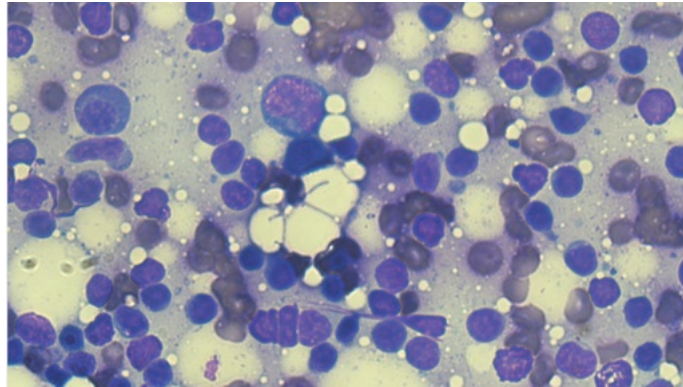
INVOICE

78161

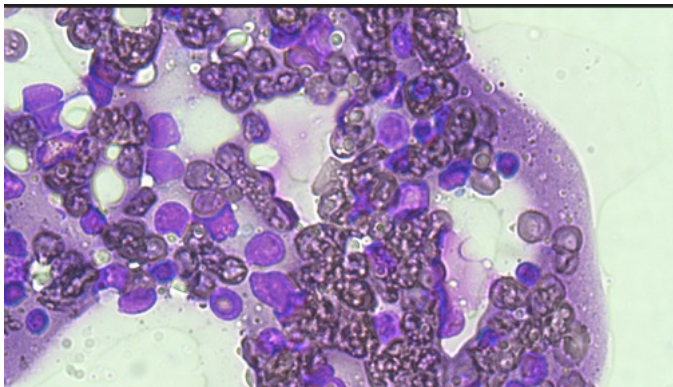
DATE

6/1/26

CYTOLOGY IMAGE



This image demonstrates a representative collection of cells from the left lymph node sample collected from Charlie. Note the large number of small lymphocytes with a plasma cell and one reactive lymphocyte.



This is a representative image of lymphocytes and red blood cells collected from the right lymph node on Charlie. There are good collections of lymphocytes in all of these images.

The information and recommendations provided are based on the images presented by the referring veterinarian/sonographer. No evaluation can be communicated regarding pathology that was not visible in the image/video clips provided.

Thank you for this referral. If the clinical or image interpretation does not parallel your findings or if I can be of any further assistance please contact me.

L.D. McGill, DVM, Ph.D., DACVP

info@sonopath.com