

PATIENT

Tonto Tokey

SPECIES

Feline

BREED

Savannah

SEX

Neutered male

AGE

13 years

WEIGHT

14 lbs

INTERPRETED BY

Dr. Lawrence McGill,
DVM, Ph.D., Diplomate,
ACVP

IMAGING PERFORMED BY

Adrienne Waffle

HOSPITAL NAME

Torch Lake VC

REFERRING VET

Dr. Waffle

INVOICE

75276

DATE

5/7/26

PRESENTING CLINICAL SIGNS

History: Patient has history of pancreatic mass and pancreatitis. FNA performed on pancreatic mass morning of 05/07/2026.

CYTOLOGY SUBMISSION

FNA of the pancreas was submitted.

OBSERVATIONS

Pancreatic aspirate: Submitted are 2 very good images of minimal numbers of cells collected from the pancreatic mass in Tonto. The cellularity is mixed with scattered neutrophils, eosinophils, lymphocytes and macrophages. Many of the macrophages have a foamy granulated cytoplasm. Degenerate debris is present in several of the images. Malignant characteristics are not identified. There is however prominent inflammation of a mixed cell type.

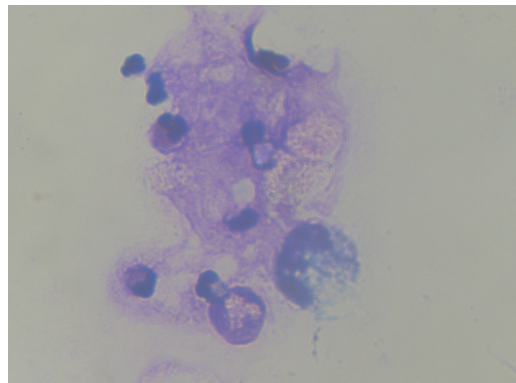
INTERPRETATION OF FINDINGS & FURTHER RECOMMENDATIONS

Pancreatic aspirate - Chronic pyogranulomatous inflammation with eosinophils and no evidence of neoplasia.

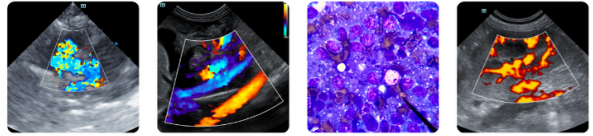
COMMENTS

The cellularity in this collection is most characteristic of a chronic inflammatory process. The specific source of the inflammatory process is likely some type of necrotizing pancreatitis. Eosinophils are prominent in the collection which is somewhat unusual. I was unable to identify any changes that would support neoplasia. With the macrophages having foamy cytoplasm and neutrophils, eosinophils and lymphocytes, this is most likely a localized chronic inflammatory process. Again there are very few cells in the images which may suggest that there is fibrosis in change of a chronic nature. A guarded prognosis is warranted both due to the potential pancreatitis and the fact that the specific source may not have been identified at this time.

CYTOLOGY IMAGE



This is an image of cells collected from the pancreas in Tonto. There are scattered eosinophils, neutrophils and macrophages with a foamy cytoplasm. The bluish gray material may be pancreatic secretions.



PATIENT

Tonto Tokey

SPECIES

Feline

BREED

Savannah

SEX

Neutered male

AGE

13 years

WEIGHT

14 lbs

INTERPRETED BY

Dr. Lawrence McGill,
DVM, Ph.D., Diplomate,
ACVP

IMAGING PERFORMED BY

Adrienne Waffle

HOSPITAL NAME

Torch Lake VC

REFERRING VET

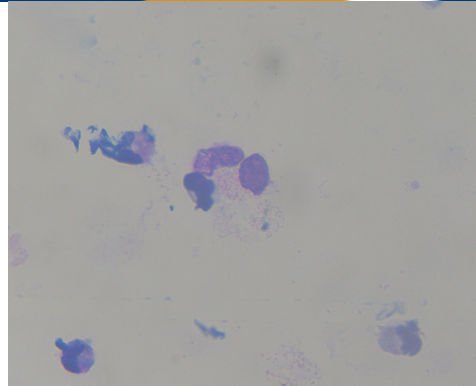
Dr, Waffle

INVOICE

75276

DATE

5/7/26



This is an image that demonstrates eosinophils with neutrophils and degenerate macrophages collected from the pancreas in Tonto.

The information and recommendations provided are based on the images presented by the referring veterinarian/sonographer. No evaluation can be communicated regarding pathology that was not visible in the image/video clips provided.

Thank you for this referral. If the clinical or image interpretation does not parallel your findings or if I can be of any further assistance please contact me.

L.D. McGill, DVM, Ph.D., DACVP

info@sonopath.com