



## PATIENT

Pablo Annabele Richy

## SPECIES

Feline

## BREED

British Shorthair

## SEX

Male

## AGE

3 years

## WEIGHT

5.8 lbs

## INTERPRETED BY

Dr. Lawrence McGill,  
DVM, Ph.D., Diplomate,  
ACVP

## IMAGING PERFORMED BY

Saddam Hussain

## HOSPITAL NAME

Pawsitive Veterinary  
Clinic Dubai Motorcity

## REFERRING VET

Dr. Inam ul haq

## INVOICE

75171

## DATE

5/4/26

## PRESENTING CLINICAL SIGNS

History: Pablo was presented with chronic coughing. Survey radiographs of the chest showed bronchial pattern

Bronchoalveolar lavage was done and the sample was submitted for interpretation

## CYTOLOGY SUBMISSION

Bronchoalveolar lavage was submitted

## OBSERVATIONS

Bronchoalveolar lavage: Submitted are 32 good images of moderate to excellent collections of cells from the bronchoalveolar lavage collected from Pablo. The cellularity is mixed with scattered epithelial cells and macrophages interspersed with lymphocytes, neutrophils, and eosinophils. Neutrophils and eosinophils are fairly prominent. I did not identify bacteria. The cellularity is inflammatory in nature and chronic.

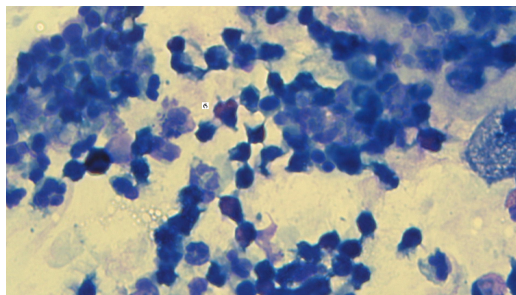
## INTERPRETATION OF FINDINGS & FURTHER RECOMMENDATIONS

Bronchoalveolar lavage - Mixed cell inflammatory process with eosinophils suggestive of feline asthma of a chronic nature or possibly feline heartworm infestation.

## COMMENTS

The cellularity supports a chronic inflammatory process. Feline asthma seems to be the most likely diagnosis although I would expect to see even more eosinophils. The number of eosinophils however could also be present in feline heartworm infestation. It does not appear to be bacterial in nature. It could be due to a chronic irritation and inhalation of some material in the environment. It is not characteristic of a neoplastic process or sepsis. Treatment for clearing the bronchioles and anti-inflammatory therapy may be beneficial. A guarded prognosis is warranted since the underlying process has not been confirmed.

## CYTOLOGY IMAGE



This image demonstrates a mixture of cells with eosinophils and a large macrophage to the right. Lymphocytes and neutrophils are scattered throughout this collection from Pablo.



## PATIENT

Pablo Annabele Richy

## SPECIES

Feline

## BREED

British Shorthair

## SEX

Male

## AGE

3 years

## WEIGHT

5.8 lbs

## INTERPRETED BY

Dr. Lawrence McGill,  
DVM, Ph.D., Diplomate,  
ACVP

## IMAGING PERFORMED BY

Saddam Hussain

## HOSPITAL NAME

Pawsitive Veterinary  
Clinic Dubai Motorcity

## REFERRING VET

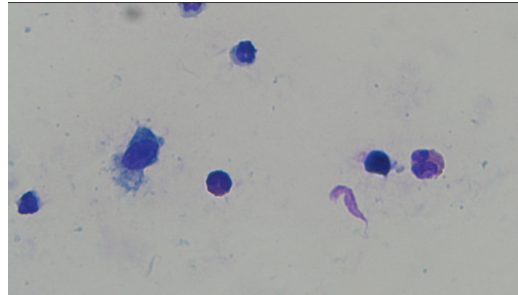
Dr. Inam ul haq

## INVOICE

75171

## DATE

5/4/26



This image demonstrates several eosinophils with neutrophils and an epithelial cell collected from the bronchoalveolar lavage from Pablo.

**The information and recommendations provided are based on the images presented by the referring veterinarian/sonographer. No evaluation can be communicated regarding pathology that was not visible in the image/video clips provided.**

Thank you for this referral. If the clinical or image interpretation does not parallel your findings or if I can be of any further assistance please contact me.

**L.D. McGill, DVM, Ph.D., DACVP**

[info@sonopath.com](mailto:info@sonopath.com)