



PATIENT

Oakley Ausfeld

SPECIES

Canine

BREED

Golden Retriever

SEX

Neutered male

AGE

7 years

WEIGHT

81 lbs

INTERPRETED BY

Dr. Lawrence McGill,
DVM, Ph.D., Diplomate,
ACVP

IMAGING PERFORMED BY

Liz LVT

HOSPITAL NAME

Rotterdam VH

REFERRING VET

Dr. Melodee Kopa

INVOICE

78140

DATE

5/29/26

PRESENTING CLINICAL SIGNS

History: Oakley is a 7 year old neutered male golden retriever who presented with a skin growth over the left mid-thoracic spine. The growth measures 8.2 mm and has a smooth, shiny pink appearance. A fine needle aspirate was performed, with a small amount of clear to pinkish fluid pulled from the growth. The patient presented as BAR with no additional concerns.

CYTOLOGY SUBMISSION

FNA of the skin mass was submitted.

OBSERVATIONS

Skin mass: Submitted are 6 good images of cells collected from the skin mass on Oakley. The majority of the images demonstrate inflammatory cells that are lymphocytes, macrophages and scattered neutrophils. One image demonstrates aggregates of cells that have a basaloid pattern. This cellularity is benign in this collection. The inflammation is prominent.

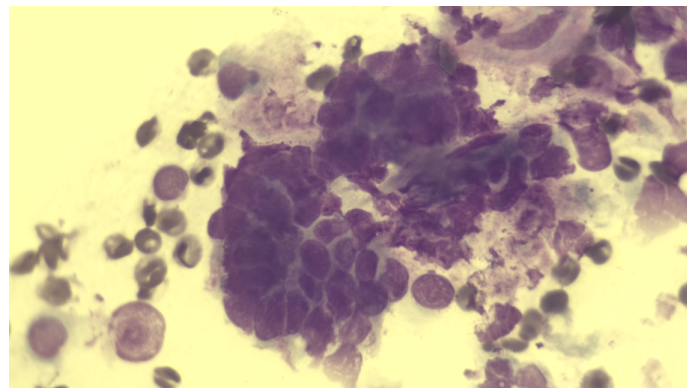
INTERPRETATION OF FINDINGS & FURTHER RECOMMENDATIONS

Skin mass - Collected are aggregates of cells suggesting basal cell proliferation with chronic inflammation.

COMMENTS

This collection demonstrates minimal numbers of proliferative cells but there is one image that suggests aggregates of basaloid cells. This could be from a basal cell tumor or could even be from a sebaceous gland adenoma or an apocrine gland proliferative process. In either instance, these are the only cells that appear to be proliferative in nature. There is secondary inflammation which commonly occurs with various cellularities such as this following trauma. Excision of the mass is encouraged. I suspect that with complete excision, a favorable prognosis can be expected.

CYTOLOGY IMAGE





PATIENT

Oakley Ausfeld

SPECIES

Canine

BREED

Golden Retriever

SEX

Neutered male

AGE

7 years

WEIGHT

81 lbs

INTERPRETED BY

Dr. Lawrence McGill,
DVM, Ph.D., Diplomate,
ACVP

IMAGING PERFORMED BY

Liz LVT

HOSPITAL NAME

Rotterdam VH

REFERRING VET

Dr. Melodee Kopa

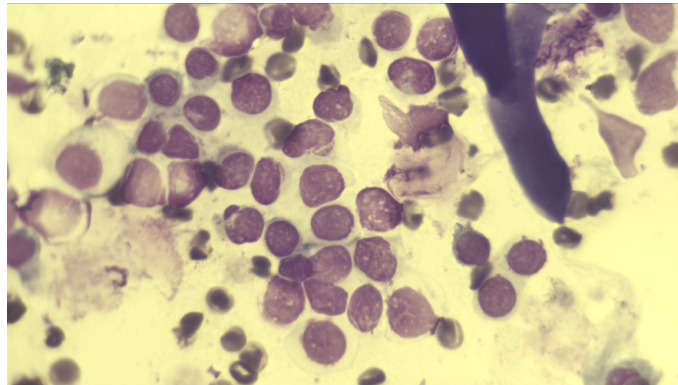
INVOICE

78140

DATE

5/29/26

This is an image that has aggregates of cells collected from the skin mass on Oakley. Note the aggregation of cells with possible chaining of the nuclei.



This is an image of cells collected from the skin mass on Oakley. This is a group of macrophages and lymphocytes with keratinized debris collected from this site. I

The information and recommendations provided are based on the images presented by the referring veterinarian/sonographer. No evaluation can be communicated regarding pathology that was not visible in the image/video clips provided.

Thank you for this referral. If the clinical or image interpretation does not parallel your findings or if I can be of any further assistance please contact me.

L.D. McGill, DVM, Ph.D., DACVP

info@sonopath.com