



## PATIENT

Charlie Oxana

## SPECIES

Canine

## BREED

Golden Retriever

## SEX

Neutered male

## AGE

12 years

## WEIGHT

37 lbs

## INTERPRETED BY

Dr. Lawrence McGill,  
DVM, Ph.D., Diplomate,  
ACVP

## IMAGING PERFORMED BY

Aiyra Gianella

## HOSPITAL NAME

Pawsitive Vetreinary  
Clinic Dubai Silicon  
Oasis

## REFERRING VET

Dr. Raza

## INVOICE

77986

## DATE

5/29/26

## PRESENTING CLINICAL SIGNS

History: Dog presented initially for evaluation of unilateral nasal discharge, occasionally accompanied by blood. Based on the clinical presentation, symptomatic treatment for an upper respiratory tract infection was initiated for one week, including antibiotics (doxycycline) and a short course of anti-inflammatory medication.

The patient returned after seven days for follow-up examination. At this visit, the left nostril showed a protruding nodular elongated tubular structure extending externally from the nasal passage. On palpation, the structure appeared firm and consistent with soft tissue proliferation picture is attached. Fine needle aspiration (FNA) was performed for cytological evaluation. Images are attached for your assessment and opinion.

## CYTOLOGY SUBMISSION

FNA of the nasal mass was submitted

## OBSERVATIONS

Nasal mass: Submitted are way too many good to excellent images many of which contain single nucleated cells. These single cell images are of little benefit in evaluating a collection particularly from a mass. The images that had large numbers of nucleated cells are potentially helpful. Due to the massive numbers of images, I was only able to evaluate slightly more than half of them.

## INTERPRETATION OF FINDINGS & FURTHER RECOMMENDATIONS

The cellularity in images that have large numbers of cells show aggregated cells that have the appearance of epithelial cells. There is prominent anisocytosis and anisokaryosis in these cells. They were packeted supporting an epithelial pattern. Many of them had an immature basaloid pattern. In images that had individualized cells, they were mainly inflammatory cells which included neutrophils and macrophages. There were scattered epithelial cells that suggested the possibility of squamous epithelial cells but the majority of the aggregated cells are small and immature.

## COMMENTS

Nasal mass - In images with large numbers of cells, there are aggregates of cells supporting a carcinoma which could be from any nasal source.

## CYTOLOGY IMAGE

The cellularity in the large aggregates of cells strongly supports some type of carcinoma. This could be a nasal carcinoma or respiratory carcinoma or possibly some other source from this location. There is secondary inflammation. Excision of the mass with a follow-up biopsy will be required to confirm the cellularity. There is adequate anisocytosis and anisokaryosis to suggest that this is a carcinoma. A guarded to unfavorable prognosis is warranted until the mass can be confirmed by biopsy.



## PATIENT

Charlie Oxana

## SPECIES

Canine

## BREED

Golden Retriever

## SEX

Neutered male

## AGE

12 years

## WEIGHT

37 lbs

## INTERPRETED BY

Dr. Lawrence McGill,  
DVM, Ph.D., Diplomate,  
ACVP

## IMAGING PERFORMED BY

Aiyra Gianella

## HOSPITAL NAME

Pawsitive Vetreinary  
Clinic Dubai Silicon  
Oasis

## REFERRING VET

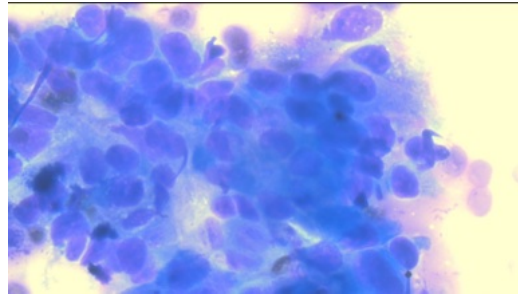
Dr. Raza

## INVOICE

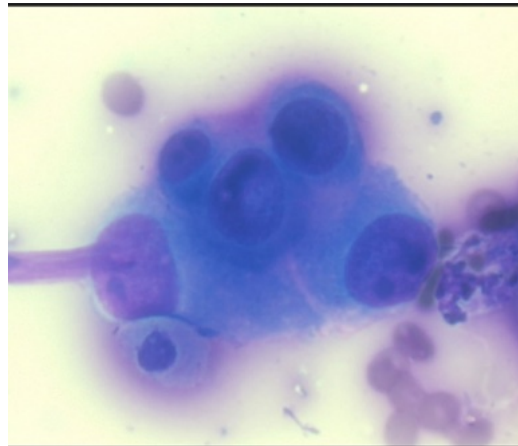
77986

## DATE

5/29/26



This is an image of aggregates of epithelial appearing cells collected from the nasal mass in Charlie. Note the aggregation and pleomorphism of the nuclei in this aggregate.



This is an image of a small group of cells demonstrating prominent anisokaryosis and anisocytosis. This is collected from the nasal mass in Charlie.

**The information and recommendations provided are based on the images presented by the referring veterinarian/sonographer. No evaluation can be communicated regarding pathology that was not visible in the image/video clips provided.**

Thank you for this referral. If the clinical or image interpretation does not parallel your findings or if I can be of any further assistance please contact me.

**L.D. McGill**, DVM, Ph.D., DACVP

[info@sonopath.com](mailto:info@sonopath.com)