



PATIENT

Barbecue Baster Laare

SPECIES

Feline

BREED

Domestic Shorthair

SEX

Male

AGE

2 ½ years

WEIGHT

3.8 kg

INTERPRETED BY

Dr. Lawrence McGill,
DVM, Ph.D., Diplomate,
ACVP

IMAGING PERFORMED BY

Dr. Iftikhar Raza

HOSPITAL NAME

Pawsitive Veterinary
Clinic Dubai Silicon
Oasis

REFERRING VET

Dr. Iftikhar Raza

INVOICE

77709

DATE

5/19/26

PRESENTING CLINICAL SIGNS

History: Barbecue has been undergoing chemotherapy since January following a diagnosis of lymphoma, and he also tested positive for feline leukemia virus (FeLV).

Since the initiation of chemotherapy, there has been significant clinical improvement. In fact, after the very first chemotherapy session, Barbecue became clinically stable. He has been monitored closely with weekly complete blood counts (CBCs) and radiographic examinations to assess the progression of the lymphoma and monitor his overall condition.

During his most recent visit last week, an ultrasonographic examination was performed, which revealed marked lymphadenopathy. Although lymphadenopathy had been consistently observed throughout previous ultrasonographic evaluations during this period, the enlargement noted last week was considerably more pronounced.

A fine-needle aspiration was therefore performed and submitted for cytological evaluation to determine whether any significant changes have occurred. Depending on the findings, an oncology consultation and possible revision of the current chemotherapeutic protocol may need to be discussed.

CYTOLOGY SUBMISSION

FNA of lymph nodes were submitted

OBSERVATIONS

Lymph node: Submitted are 29 very good images of very good collections of cells from the mesenteric lymph node in Barbecue Baster. The cellularity includes large numbers of lymphoid cells the majority of which are small to slightly intermediate lymphoid cells with very rare large lymphoid cells. Neutrophils are present in many of the images. Atypical lymphoid cells are not identified. The large lymphoid cells suggest reactivity.

INTERPRETATION OF FINDINGS & FURTHER RECOMMENDATIONS

Lymph node - Reactive lymph node with mild chronic suppurative lymphadenitis.

COMMENTS

The cellularity in this collection suggests the likelihood of a chronic inflammatory process draining to these lymph nodes. This inflammation could be from any location in the abdominal cavity including pancreatitis or enteritis. There could be systemic inflammation as well. The cellularity is not characteristic of lymphoma. There is an outside possibility of lymphoma and the only means for confirming that would be with PARR testing. I am not certain that this is required in this case. There are more changes in these very good images that support inflammation and reactive lymphoid tissue than malignancy. Treatment for inflammation can be considered.



PATIENT

Barbecue Baster Laare

SPECIES

Feline

BREED

Domestic Shorthair

SEX

Male

AGE

2 ½ years

WEIGHT

3.8 kg

INTERPRETED BY

Dr. Lawrence McGill,
DVM, Ph.D., Diplomate,
ACVP

IMAGING PERFORMED BY

Dr. Iftikhar Raza

HOSPITAL NAME

Pawsitive Veterinary
Clinic Dubai Silicon
Oasis

REFERRING VET

Dr. Iftikhar Raza

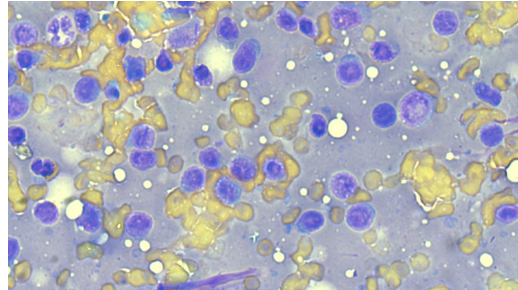
INVOICE

77709

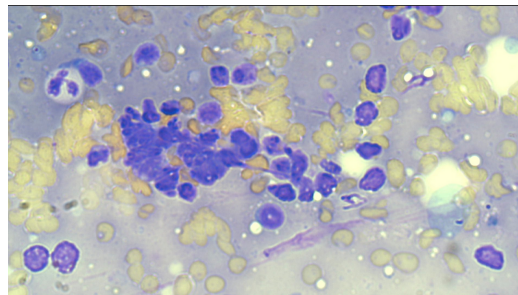
DATE

5/19/26

CYTOLOGY IMAGE



This is an image representing the lymphoid cells with many small to slightly intermediate lymphoid cells and very few large lymphoid cells and a neutrophil in the upper left collected from the mesenteric lymph node in Barbecue Baster.



This is a second image of lymphoid cells demonstrating mainly small lymphocytes with a neutrophil in the upper left corner of the aspirate from the lymph node in Barbecue Baster.

The information and recommendations provided are based on the images presented by the referring veterinarian/sonographer. No evaluation can be communicated regarding pathology that was not visible in the image/video clips provided.

Thank you for this referral. If the clinical or image interpretation does not parallel your findings or if I can be of any further assistance please contact me.

L.D. McGill, DVM, Ph.D., DACVP

info@sonopath.com