



## PATIENT

Pacco Metcalf

## SPECIES

Canine

## BREED

German Shepherd

## SEX

Intact male

## AGE

8 years

## WEIGHT

80 lbs

## INTERPRETED BY

Dr. Lawrence McGill,  
DVM, Ph.D., Diplomate,  
ACVP

## IMAGING PERFORMED BY

Karen Ebersole, DVM,  
DABVP (Canine &  
Feline)

## HOSPITAL NAME

Scanvet

## REFERRING VET

Dr. McGarvey

## INVOICE

77660

## DATE

5/18/26

## PRESENTING CLINICAL SIGNS

History: Persistent hematuria. FNA large splenic nodule.  
AUS: Right kidney mass, large splenic nodules and few small liver nodules. Mild BPH pattern. +++ sediment in urinary bladder. BW - WNL. Unable to get free catch UA.

## CYTOLOGY SUBMISSION

FNA of the spleen was submitted

## OBSERVATIONS

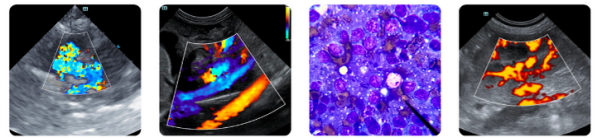
Spleen: Submitted are 9 excellent videos of moderate to excellent collections of cells from the spleen in Pacco. The cellularity is mixed through much of the collection with many clumps of cells. Some of the clumps demonstrate histiocytic cells interspersed with nucleated RBCs. There are other clumps of cells that demonstrate prominent anisocytosis and anisokaryosis and apparent mitotic figures. These aggregates are clumped and in fact produce rosette aggregates. The cellularity suggests a neoplastic process in the spleen.

## INTERPRETATION OF FINDINGS & FURTHER RECOMMENDATIONS

Spleen - Aggregates of cells suggesting malignancy with prominent splenitis and extra medullary hematopoiesis.

## COMMENTS

The cellularity in this collection strongly suggests a neoplastic process in the spleen. These cells are possibly carcinoma cells or they could even be some type of a histiocytic neoplastic process but I do not think that they are lymphoid in nature. There is evidence of prominent splenitis and other changes. Confirmation of the source for these prominent neoplastic cells will require a follow-up biopsy either by splenectomy or by biopsy of the kidney. I'm strongly suspicious of a metastatic neoplastic process to the spleen. A guarded to unfavorable prognosis is warranted after evaluating these cells.



## PATIENT

Pacco Metcalf

## SPECIES

Canine

## BREED

German Shepherd

## SEX

Intact male

## AGE

8 years

## WEIGHT

80 lbs

## INTERPRETED BY

Dr. Lawrence McGill,  
DVM, Ph.D., Diplomate,  
ACVP

## IMAGING PERFORMED BY

Karen Ebersole, DVM,  
DABVP (Canine &  
Feline)

## HOSPITAL NAME

Scanvet

## REFERRING VET

Dr. McGarvey

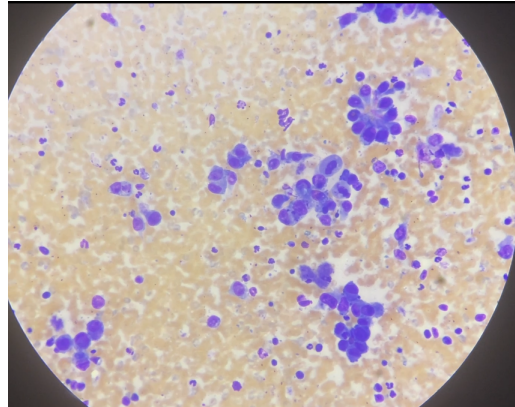
## INVOICE

77660

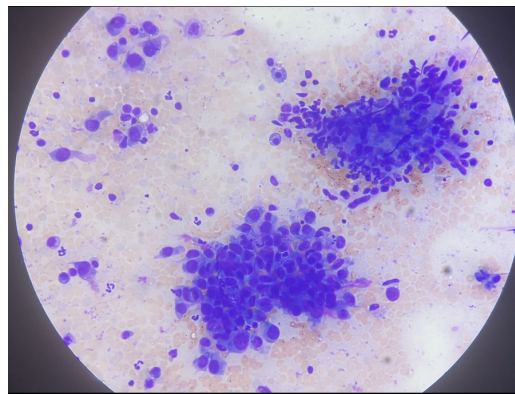
## DATE

5/18/26

## CYTOLOGY IMAGE



This is an image of a group of cells demonstrating a mitotic figure in the center collected from the spleen in Pacco. Note the rosette in the upper right.



This image demonstrates a group of apparent neoplastic cells in the lower center with aggregates of histiocytic cells and nucleated RBCs to the upper right demonstrating different cellularity in multiple locations in this collection from the spleen in Pacco.

**The information and recommendations provided are based on the images presented by the referring veterinarian/sonographer. No evaluation can be communicated regarding pathology that was not visible in the image/video clips provided.**

Thank you for this referral. If the clinical or image interpretation does not parallel your findings or if I can be of any further assistance please contact me.

**L.D. McGill, DVM, Ph.D., DACVP**

[info@sonopath.com](mailto:info@sonopath.com)