



PATIENT

Caicai Lazaro

SPECIES

Canine

BREED

Shiba Inu

SEX

Male

AGE

4 Months

WEIGHT

6.8 kg

INTERPRETED BY

Dr. Lawrence McGill,
DVM,Ph.D.,Diplomate,
ACVP

IMAGING PERFORMED BY

Dr. Kyrollos Salib

HOSPITAL NAME

Pawsitive Vet Clinic
Dubai Silicon Oasis

REFERRING VET

Dr. Kyrollos Salib

INVOICE

75209

DATE

5/17/26

PRESENTING CLINICAL SIGNS

A 4 months old Shiba Inu intact male dog presented with a small mass on his lateral side of the neck. The mass is around 3-4cm wide red and elevated from the skin level with 1 cm height. It's non painful but probably irritating because the dog scratched it before.

CYTOLOGY SUBMISSION

Skin mass.

OBSERVATIONS

Submitted are 89 very good images of excellent collections of cells in most of the images submitted and collected from Caicai. Almost all of the cells are mononuclear cells. There are rare neutrophils but the mononuclear cells are massive in the collection. The mononuclear cells have bluish gray cytoplasm in many cases and there are small mature lymphocytes scattered throughout. Some of the cells have the pattern of lymphocytes but others are demonstrating centrally located round nuclei which suggests a fried egg pattern. All of the cells except for a very few neutrophils are round cells.

INTERPRETATION OF FINDINGS & FURTHER RECOMMENDATIONS

Round cell collection suggestive of inflamed histiocytoma or possible lymphocytic nodule.

COMMENTS

The cellularity is entirely round cells which suggests the possibility of an inflamed histiocytoma since some of the cells appear to be larger with prominent cytoplasm. Other malignant characteristics are not identified. There are lymphocytes present throughout the collection and this could also be a localized lymphocytic nodule secondary to an insect sting or potential foreign body penetration. Monitoring the area for the next several weeks for regression would be encouraged. As you well know, histiocytomas will commonly regress on their own. If there is no regression within 3 to 4 weeks, then excision of the mass may be required as a follow-up biopsy. It may be an inflammatory process. I am expecting a good prognosis but continued monitoring is encouraged.

CYTOLOGY IMAGE

Below is an image that includes large numbers of round cells with some small lymphocytes in the skin mass aspirate from Caicai. Note that some of the cells have a fried egg appearance.



PATIENT

Caicai Lazaro

SPECIES

Canine

BREED

Shiba Inu

SEX

Male

AGE

4 Months

WEIGHT

6.8 kg

INTERPRETED BY

Dr. Lawrence McGill,
DVM,Ph.D.,Diplomate,
ACVP

IMAGING PERFORMED BY

Dr. Kyrollos Salib

HOSPITAL NAME

Pawsitive Vet Clinic
Dubai Silicon Oasis

REFERRING VET

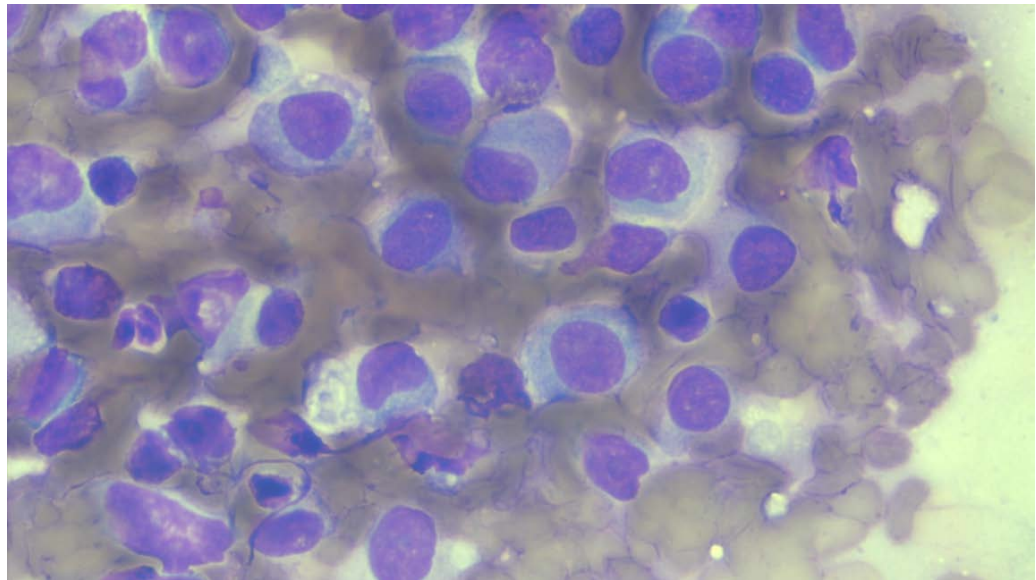
Dr. Kyrollos Salib

INVOICE

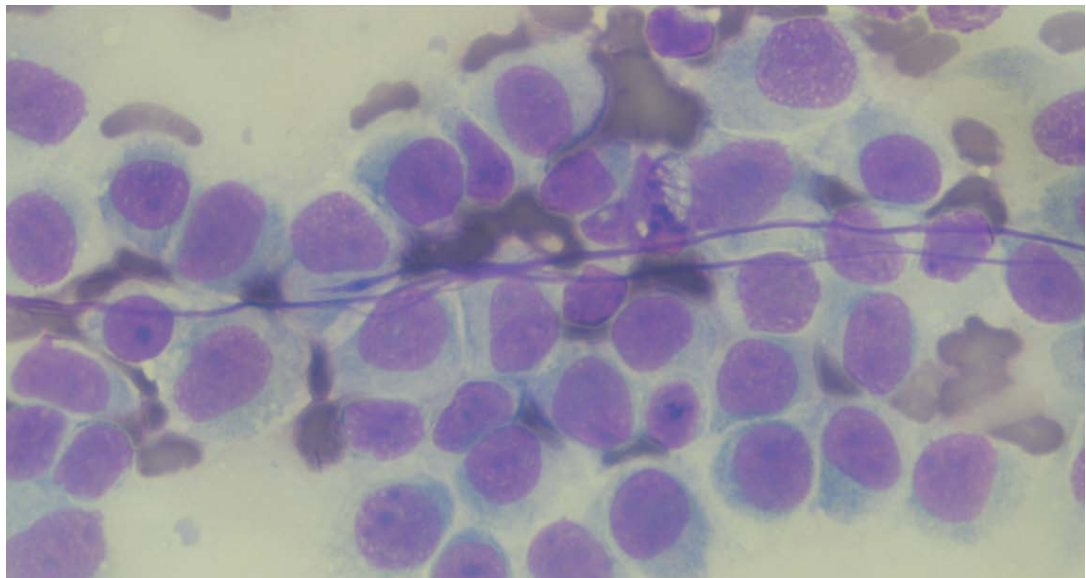
75209

DATE

5/17/26



Below is an image of a group of round cells collected from the skin mass on Caicai. Note the uniformity of the round cells and the central located nucleus in several.



The information and recommendations provided are based on the images presented by the referring veterinarian/sonographer. No evaluation can be communicated regarding pathology that was not visible in the image/video clips provided.

Thank you for this referral. If the clinical or image interpretation does not parallel your findings or if I can be of any further assistance please contact me.

L.D. McGill, DVM, Ph.D., DACVP

info@sonopath.com