



PATIENT

Cooper Lana Mencil

SPECIES

Feline

BREED

Domesetic Short Hair

SEX

Male

AGE

5 Months

WEIGHT

2.7 kg

INTERPRETED BY

Dr. Lawrence McGill,
DVM,Ph.D.,Diplomate,
ACVP

IMAGING PERFORMED BY

Dr. Hamza

HOSPITAL NAME

Creekside Veterinary
Clinic

REFERRING VET

Dr. Hamza

INVOICE

75197

DATE

5/16/26

PRESENTING CLINICAL SIGNS

A 5-month-old kitten presented with a solitary swelling/lump located in the axillary region below the forelimb. On clinical examination, the mass was palpable in the subcutaneous tissue, and fine needle aspiration (FNA) was performed aseptically for cytological evaluation to determine the nature of the lesion.

CYTOLOGY SUBMISSION

Axillary mass.

OBSERVATIONS

Submitted are 23 very good images of cells collected from the axillary mass on Cooper. Many of the cells in the images are smudged nuclear debris or necrotic material. Neutrophils are identified in many of the images. I did not identify any bacteria. There is no suggestion of neoplasia in the collection. There is severe suppurative inflammation and necrosis.

INTERPRETATION OF FINDINGS & FURTHER RECOMMENDATIONS

Necrosis and inflammation consistent with an abscess.

COMMENTS

The cellularity supports a severe inflammatory process with necrosis. It is almost entirely neutrophilia with respect to cells that can be identified. This suggests a localized necrotizing process which could be secondary to foreign body penetration or trauma or localized steatitis. The cause was not identified. The inflammation appears to be severe. I did not identify any bacteria and the images were adequate to identify those if they were present. However the number of viable cells is few and there may be bacteria present that were not in these images. Treatment with anti-inflammatory products and antibiotics may be beneficial. Continued monitoring to see if the lesion grows or causes more inflammation is encouraged.

CYTOLOGY IMAGE

Below is an image that demonstrates many of the degenerate cells with scattered neutrophils in the collection. This is a sample of cells collected from the axillary region on Cooper.



PATIENT

Cooper Lana Mencil

SPECIES

Feline

BREED

Domesetic Short Hair

SEX

Male

AGE

5 Months

WEIGHT

2.7 kg

INTERPRETED BY

Dr. Lawrence McGill,
DVM,Ph.D.,Diplomate,
ACVP

IMAGING PERFORMED BY

Dr. Hamza

HOSPITAL NAME

Creekside Veterinary
Clinic

REFERRING VET

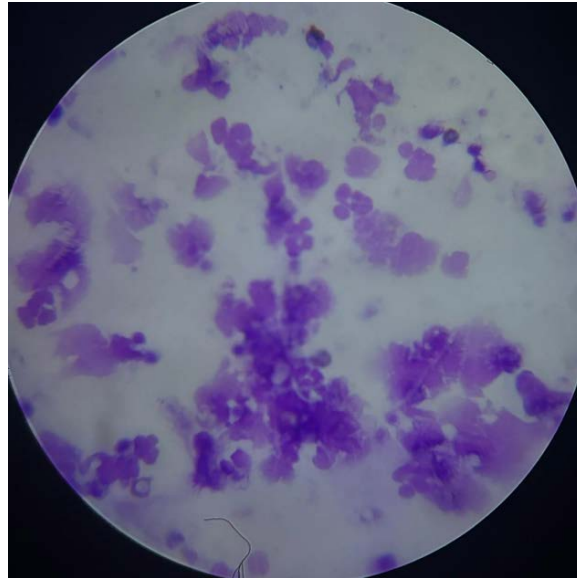
Dr. Hamza

INVOICE

75197

DATE

5/16/26



The information and recommendations provided are based on the images presented by the referring veterinarian/sonographer. No evaluation can be communicated regarding pathology that was not visible in the image/video clips provided.

Thank you for this referral. If the clinical or image interpretation does not parallel your findings or if I can be of any further assistance please contact me.

L.D. McGill, DVM, Ph.D., DACVP

info@sonopath.com