



PATIENT

Leila Marquart

SPECIES

Feline

BREED

Domestic Shorthair

SEX

Spayed Female

AGE

13 years

WEIGHT

6.3 lbs

INTERPRETED BY

Dr. Lawrence McGill,
DVM, Ph.D., Diplomate,
ACVP

IMAGING PERFORMED BY

Nick Pizzemento

HOSPITAL NAME

Central VH

REFERRING VET

Dr. Anna St Sir

INVOICE

77613

DATE

5/15/26

PRESENTING CLINICAL SIGNS

History: Anorexia, weight loss. On U/S - liver is normal size, sharp edges, hypoechoic, coarse
Abnormal PE/Chem/CBC/UA Results: Elevated liver enzymes

CYTOLOGY SUBMISSION

FNA of the liver was submitted

OBSERVATIONS

Liver: Submitted are 9 excellent videos of moderate to excellent collections of cells from the liver in Leila. The cellularity consists of good collections of hepatocytes interspersed throughout red blood cells. The hepatocytes appear to be relatively uniform with granular cytoplasm. Scattered cells are slightly vacuolated. The surrounding cellularity includes scattered neutrophils and a few lymphocytes. Malignant characteristics are not identified.

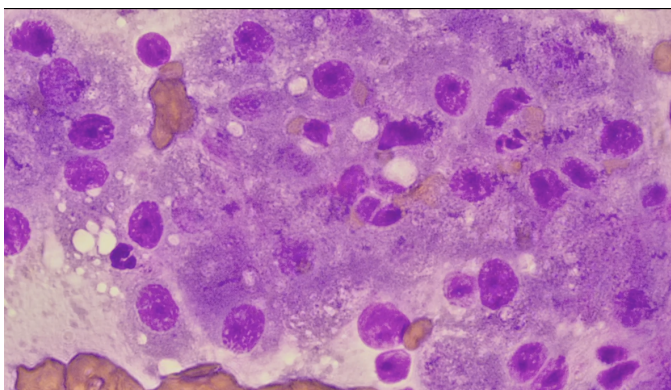
INTERPRETATION OF FINDINGS & FURTHER RECOMMENDATIONS

Liver - Mild hepatocellular vacuolization and moderate granularity with mild chronic suppurative hepatitis.

COMMENTS

The cellularity demonstrates good collections of hepatocytes with a suggestion of inflammation. The inflammatory cells include neutrophils. There is no suggestion of malignancy or sepsis. This appears to be secondary inflammation and possible secondary lymphocytic cholangiohepatitis. This hepatitis easily could be due to pancreatitis or enteritis as a secondary reaction. A guarded prognosis is warranted due to the fact that these changes are likely secondary and not primary. If problems continue, further evaluation for pancreatitis or enteritis or other sources of inflammation that might affect the liver secondarily would be encouraged. The changes observed are most likely secondary

CYTOLOGY IMAGE



This is an image of hepatocytes collected from the liver in Leila. Note the scattered neutrophils in the collection.



PATIENT

Leila Marquart

SPECIES

Feline

BREED

Domestic Shorthair

SEX

Spayed Female

AGE

13 years

WEIGHT

6.3 lbs

INTERPRETED BY

Dr. Lawrence McGill,
DVM, Ph.D., Diplomate,
ACVP

IMAGING PERFORMED BY

Nick Pizzemento

HOSPITAL NAME

Central VH

REFERRING VET

Dr. Anna St Sir

INVOICE

77613

DATE

5/15/26

The information and recommendations provided are based on the images presented by the referring veterinarian/sonographer. No evaluation can be communicated regarding pathology that was not visible in the image/video clips provided.

Thank you for this referral. If the clinical or image interpretation does not parallel your findings or if I can be of any further assistance please contact me.

L.D. McGill, DVM, Ph.D., DACVP

info@sonopath.com