



PATIENT

Boomer Lucy

SPECIES

Canine

BREED

Labrador Retriever

SEX

Neutered male

AGE

8 years

WEIGHT

91 lbs

INTERPRETED BY

Dr. Lawrence McGill,
DVM, Ph.D., Diplomate,
ACVP

IMAGING PERFORMED BY

Karen Ebersole, DVM,
DABVP

HOSPITAL NAME

Scanvet

REFERRING VET

Dr. McGarvey

INVOICE

75293

DATE

5/11/26

PRESENTING CLINICAL SIGNS

History: History of chronic vomiting, possible mass effect on Radiographs. FNA Spleen.
Abnormal PE/Chem/CBC/UA Results: PE: WNL RADS - soft tissue density displacing SI. Concern for splenomegaly and/or splenic mass AUS - Mild splenomegaly with diffuse mild to mod. heterogeneous parenchyma. No capsule expansion. Folded spleen cranially. Aging changes in both kidneys. NSF otherwise.

CYTOLOGY SUBMISSION

FNA of the spleen was submitted

OBSERVATIONS

Spleen: Submitted are 8 excellent videos of excellent collections of cells from the spleen in Boomer. The cellularity is mixed. Neutrophils are readily identified interspersed with mature lymphocytes and scattered macrophages. There are aggregates of cells that suggest nucleated red blood cells with macrophages and megakaryocytes. Malignant characteristics are not suggested. The cellularity is most consistent with inflammation.

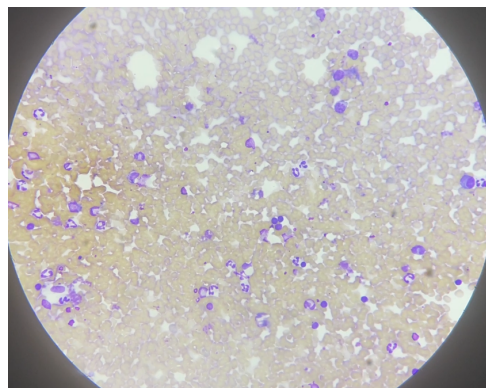
INTERPRETATION OF FINDINGS & FURTHER RECOMMENDATIONS

Spleen - Consistent with splenitis with reactive splenic tissue.

COMMENTS

The splenic tissue is most characteristic of a chronic inflammatory process. This could be secondary to many different conditions in the abdominal cavity or systemic infection in the dog. There is no suggestion of malignancy. Chronic pancreatitis or enteritis is certainly suggested to be evaluated in Boomer. Other systemic inflammatory processes could be involved. Treatment for chronic inflammation may be beneficial in Boomer.

CYTOLOGY IMAGE



This is an image that is representative of the cells collected from the spleen in Boomer. Note the large number of neutrophils interspersed with reactive lymphocytes and macrophages collected from this sample.



PATIENT

Boomer Lucy

SPECIES

Canine

BREED

Labrador Retriever

SEX

Neutered male

AGE

8 years

WEIGHT

91 lbs

INTERPRETED BY

Dr. Lawrence McGill,
DVM, Ph.D., Diplomate,
ACVP

IMAGING PERFORMED BY

Karen Ebersole, DVM,
DABVP

HOSPITAL NAME

Scanvet

REFERRING VET

Dr. McGarvey

INVOICE

75293

DATE

5/11/26

The information and recommendations provided are based on the images presented by the referring veterinarian/sonographer. No evaluation can be communicated regarding pathology that was not visible in the image/video clips provided.

Thank you for this referral. If the clinical or image interpretation does not parallel your findings or if I can be of any further assistance please contact me.

L.D. McGill, DVM, Ph.D., DACVP

info@sonopath.com