



PATIENT

Ava Ercolano

SPECIES

Canine

BREED

Rottweiler

SEX

Spayed female

AGE

11 years

WEIGHT

87.8 lbs

INTERPRETED BY

Dr. Lawrence McGill,
DVM, Ph.D., Diplomate,
ACVP

IMAGING PERFORMED BY

Erin LVT

HOSPITAL NAME

Rotterdam VH

REFERRING VET

Dr. Anna St Sir

INVOICE

74348

DATE

4/9/26

PRESENTING CLINICAL SIGNS

History: Patient presented for swelling lower eyelid OS 4/1/26. Anesthetized for dental procedure 4/9/26 - oral mass found under hard palate @ TMJ junction left side. FNA taken for pathology review.

CYTOLOGY SUBMISSION

FNA of the oral mass was submitted.

OBSERVATIONS

Oral mass: Submitted are 7 excellent images of cells collected from the oral mass in Ava. There is a background of red blood cells in all of the images but there are scattered polyhedral to rounded cells that occasionally are aggregated throughout the collection. There is a bluish gray cytoplasm in the cells with round irregular nuclei. Occasionally there's a yellowish-brown granular material in some of the cells. The aggregation and cellularity is characteristic of a probable neoplastic process.

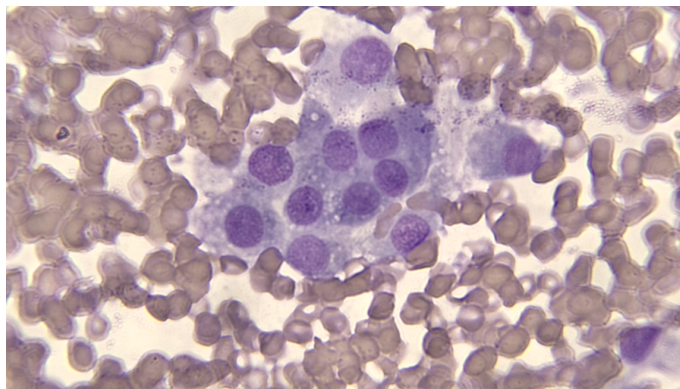
INTERPRETATION OF FINDINGS & FURTHER RECOMMENDATIONS

Oral mass - Proliferative cells suggestive of amelanotic malignant melanoma.

COMMENTS

The cellularity supports a neoplastic process but the specific cell type is not confirmed. There are some granules that suggest the possibility of melanin granules and I'm concerned about an amelanotic malignant melanoma. Wide excision of the mass with a follow-up biopsy will be required to confirm the underlying process. Special stains may be required since there are minimal numbers of granules in the cells. A guarded to unfavorable prognosis is warranted in my opinion due to this irregular cellularity and the potential for metastasis.

CYTOLOGY IMAGE



This is an image of a group of apparent tumor cells with prominent anisokaryosis and scattered granular structures that could be melanin collected from the oral mass in Ava.



PATIENT

Ava Ercolano

SPECIES

Canine

BREED

Rottweiler

SEX

Spayed female

AGE

11 years

WEIGHT

87.8 lbs

INTERPRETED BY

Dr. Lawrence McGill,
DVM, Ph.D., Diplomate,
ACVP

IMAGING PERFORMED BY

Erin LVT

HOSPITAL NAME

Rotterdam VH

REFERRING VET

Dr. Anna St Sir

INVOICE

74348

DATE

4/9/26

The information and recommendations provided are based on the images presented by the referring veterinarian/sonographer. No evaluation can be communicated regarding pathology that was not visible in the image/video clips provided.

Thank you for this referral. If the clinical or image interpretation does not parallel your findings or if I can be of any further assistance please contact me.

L.D. McGill, DVM, Ph.D., DACVP

8288 Top of the World Dr. Cottonwood Heights, UT 84121

Cell: 801-865-1220 Ldmcgill.vetpath@gmail.com