



## PATIENT

Raven Buchanan

## SPECIES

Canine

## BREED

Kerry Blue Terrier

## SEX

Spayed female

## AGE

14 years

## WEIGHT

26 lbs

## INTERPRETED BY

Dr. Lawrence McGill,  
DVM, Ph.D., Diplomate,  
ACVP

## IMAGING PERFORMED BY

Nick Pizzemento

## HOSPITAL NAME

Central VH

## REFERRING VET

Dr. Anna St Sir

## INVOICE

74209

## DATE

4/6/26

## PRESENTING CLINICAL SIGNS

- Vomiting, weight loss. On abdominal ultrasound - hypoechoic irregular mass (1.5 cm diameter) caudal abdomen, does not appear to be attached to any organs

## CYTOLOGY SUBMISSION

FNA of the caudal abdominal mass was submitted

## OBSERVATIONS

Caudal abdominal mass: Submitted is 1 excellent video and 1 excellent image of cells and material collected from the caudal abdominal mass in Raven. The cellularity is minimal but consists of adipose tissue and cells that could be mesothelial cells or macrophages. Many of the cells have a foamy vacuolated cytoplasm. Some granularity to the cytoplasm has also occurred. Malignant characteristics are not confirmed. These cells could be macrophages or mesothelial cells.

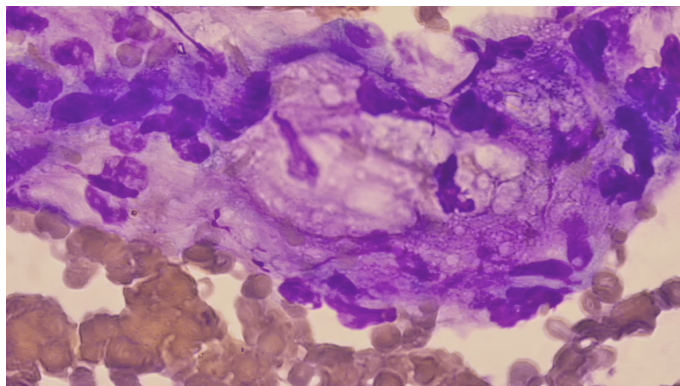
## INTERPRETATION OF FINDINGS & FURTHER RECOMMENDATIONS

Caudal abdominal mass - Aggregates of cells including lipid and probable macrophages or mesothelial cells.

## COMMENTS

The cellularity supports the likelihood of some type of chronic inflammatory process. I would wonder about the possibility of inflammation in the mesentery or possibly some nonspecific inflammatory reaction. I am unable to confirm malignancy but that is a possibility of some type of low-grade proliferative process. This mass could be causing a mass response in the abdomen. Again the specific source is not confirmed. Exploratory and excision will be required to confirm the process. A guarded prognosis is warranted until the mass can be confirmed by biopsy.

## CYTOLOGY IMAGE



This is an image of some of these cells collected in the video demonstrating the prominent lipid with scattered irregular cells and irregular nuclei collected from the caudal abdominal mass in Raven.



## PATIENT

Raven Buchanan

## SPECIES

Canine

## BREED

Kerry Blue Terrier

## SEX

Spayed female

## AGE

14 years

## WEIGHT

26 lbs

## INTERPRETED BY

Dr. Lawrence McGill,  
DVM, Ph.D., Diplomate,  
ACVP

## IMAGING PERFORMED BY

Nick Pizzemento

## HOSPITAL NAME

Central VH

## REFERRING VET

Dr. Anna St Sir

## INVOICE

74209

## DATE

4/6/26

The information and recommendations provided are based on the images presented by the referring veterinarian/sonographer. No evaluation can be communicated regarding pathology that was not visible in the image/video clips provided.

Thank you for this referral. If the clinical or image interpretation does not parallel your findings or if I can be of any further assistance please contact me.

**L.D. McGill, DVM, Ph.D., DACVP**

8288 Top of the World Dr. Cottonwood Heights, UT 84121

Cell: 801-865-1220 [Ldmcgill.vetpath@gmail.com](mailto:Ldmcgill.vetpath@gmail.com)