



PATIENT

Jimmy Ferreira

SPECIES

Feline

BREED

Domestic Shorthair

SEX

Neutered male

AGE

10 years

WEIGHT

9 kg

INTERPRETED BY

Dr. Lawrence McGill,
DVM, Ph.D., Diplomate,
ACVP

IMAGING PERFORMED BY

Dr. Sadovoi

HOSPITAL NAME

Pawsitive Veterinary
Clinic Dubai Silicon
Oasis

REFERRING VET

Dr. Sadovoi

INVOICE

74743

DATE

4/22/26

PRESENTING CLINICAL SIGNS

History: Owner realized that cat having red spots on his belly, before yesterday it was very less, but now it's more. Otherwise conditions like appetite and activity levels are the same. No diarrhea or vomit was observed. Cat fight with another cats outside. By the observation on the right side palpable mass, painful under palpation. Nipple and skin near the growth is hemorrhagic, approximately because of licking or blind trauma. Cat was castrated long ago when he was above one year old.

CYTOLOGY SUBMISSION

FNA of the skin lesions were submitted

OBSERVATIONS

Skin lesions: Submitted are 55 excellent images of excellent collections of cells from the abdominal skin lesions on Jimmy. There is a background of red blood cells but the majority of the nucleated cells are neutrophils. There are aggregates of bacteria in the cytoplasm of the neutrophils and in the surrounding tissue. The bacteria appear to be coccoid bacteria in clumps and scattered rod shaped bacteria. Other cellular changes are not identified. There is no suggestion of malignant characteristics.

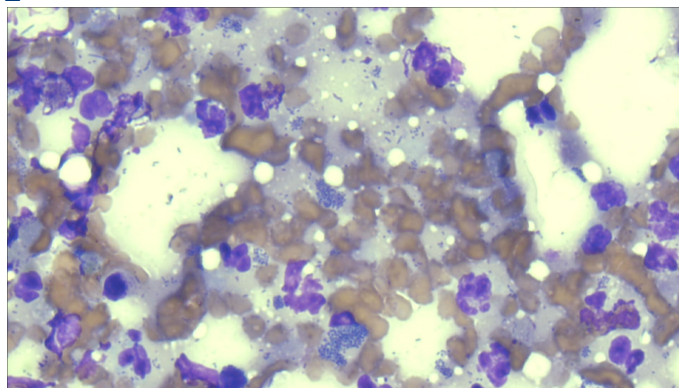
INTERPRETATION OF FINDINGS & FURTHER RECOMMENDATIONS

Skin lesions - Pyoderma with bacterial infection.

COMMENTS

The cellularity in this collection includes large numbers of bacteria with a suppurative response. There is no suggestion of malignancy or other types of inflammation. Bacterial culture may be beneficial in confirming the underlying organism. Antibiotic therapy with anti-inflammatory therapy is encouraged. A guarded prognosis is warranted until the underlying bacteria and susceptibility of the organisms can be confirmed.

CYTOLOGY IMAGE



This is an image of cells collected from the abdominal skin lesions on Jimmy. Note the large number of neutrophils interspersed with bacteria and bacteria in many of the neutrophils. Culture is encouraged.



PATIENT

Jimmy Ferreira

SPECIES

Feline

BREED

Domestic Shorthair

SEX

Neutered male

AGE

10 years

WEIGHT

9 kg

INTERPRETED BY

Dr. Lawrence McGill,
DVM, Ph.D., Diplomate,
ACVP

IMAGING PERFORMED BY

Dr. Sadovoi

HOSPITAL NAME

Pawsitive Veterinary
Clinic Dubai Silicon
Oasis

REFERRING VET

Dr. Sadovoi

INVOICE

74743

DATE

4/22/26

The information and recommendations provided are based on the images presented by the referring veterinarian/sonographer. No evaluation can be communicated regarding pathology that was not visible in the image/video clips provided.

Thank you for this referral. If the clinical or image interpretation does not parallel your findings or if I can be of any further assistance please contact me.

L.D. McGill, DVM, Ph.D., DACVP

info@sonopath.com