



PATIENT

Isabelle Allmond

SPECIES

Feline

BREED

Domestic Shorthair

SEX

Spayed female

AGE

12 years

WEIGHT

9.4 lbs

INTERPRETED BY

Dr. Lawrence McGill,
DVM, Ph.D., Diplomate,
ACVP

IMAGING PERFORMED BY

Nick Pizzemento

HOSPITAL NAME

Central VH

REFERRING VET

Dr. Anna St Sir

INVOICE

74711

DATE

4/21/26

PRESENTING CLINICAL SIGNS

History: FNA taken from lymph node near left lobe of pancreas. Significant inflammation present. Patient had intestinal lymphoma that was resected and was on chemotherapy treatment in 2022.

CYTOLOGY SUBMISSION

FNA of the lymph node was submitted

OBSERVATIONS

Lymph node: Submitted are 8 excellent videos of excellent collections of cells from the mesenteric lymph node in Isabelle. The cellularity is mainly round cells which are lymphoid cells and a large number of those cells are small mature lymphocytes. Reactive lymphoid cells are identified scattered throughout. There are scattered large macrophages with granular to foamy cytoplasm and scattered neutrophils. Some of the lymphoid cells are large and others demonstrate intermediate lymphoid cells but the majority of the cells are small mature lymphocytes. There is a background of red blood cells.

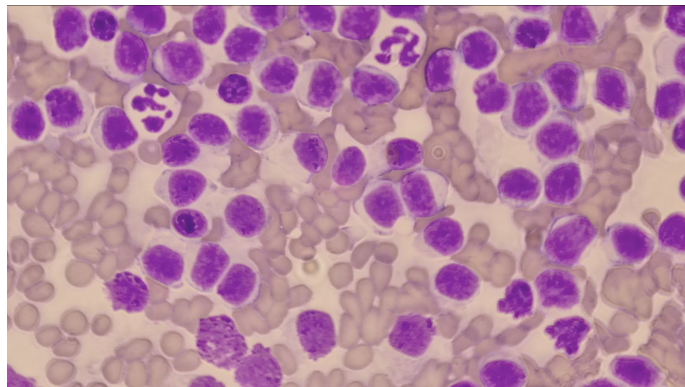
INTERPRETATION OF FINDINGS & FURTHER RECOMMENDATIONS

Lymph node - Consistent with reactive or stimulated lymph node with mild suppurative or granulomatous inflammation.

COMMENTS

The cellularity in this collection is strongly suggestive of a reactive lymph node tissue with chronic inflammation. The inflammation could be from the pancreas or pancreatitis or could even be associated with FIP. The cellularity is not classical for malignancy but I cannot completely rule out that potential. If further diagnostics are desired, these slides can be sent to a laboratory for PARR testing. With these images, I am more suspicious of chronic inflammation and reactive or stimulated lymph node. A guarded prognosis of course is warranted since the underlying process is not confirmed.

CYTOLOGY IMAGE



This is an image representing many of the cells in the lymph node aspirate from Isabelle. Note the neutrophils and the lymphoid cells that are smaller than the neutrophils in this collection. Other fields had large numbers of very small lymphoid cells.



PATIENT

Isabelle Allmond

SPECIES

Feline

BREED

Domestic Shorthair

SEX

Spayed female

AGE

12 years

WEIGHT

9.4 lbs

INTERPRETED BY

Dr. Lawrence McGill,
DVM, Ph.D., Diplomate,
ACVP

IMAGING PERFORMED BY

Nick Pizzemento

HOSPITAL NAME

Central VH

REFERRING VET

Dr. Anna St Sir

INVOICE

74711

DATE

4/21/26

The information and recommendations provided are based on the images presented by the referring veterinarian/sonographer. No evaluation can be communicated regarding pathology that was not visible in the image/video clips provided.

Thank you for this referral. If the clinical or image interpretation does not parallel your findings or if I can be of any further assistance please contact me.

L.D. McGill, DVM, Ph.D., DACVP

info@sonopath.com