



## PATIENT

Mickey Silverstein

## SPECIES

Feline

## BREED

DSH

## SEX

Spayed Female

## AGE

15 Years

## WEIGHT

14.3 lbs

## INTERPRETED BY

Dr. Lawrence McGill,  
DVM, Ph.D., Diplomate,  
ACVP

## IMAGING PERFORMED BY

Nick Pizzemento

## HOSPITAL NAME

Central Veterinary  
Hospital

## REFERRING VET

Dr. Michel Hardaker

## INVOICE

74559

## DATE

4/17/26

## PRESENTING CLINICAL SIGNS

2 day history of inappetence. vomited once. last seen for physical exam 5 years ago. abdomen is painful to palpation with no masses appreciated.

AUS: normal except a single nodule/area on pancreas identified for aspirate. fPL elevated @ 7.3 with rest of BW unremarkable.

## CYTOLOGY SUBMISSION

Pancreas.

## OBSERVATIONS

Submitted are 10 excellent videos of minimal to moderate collections of cells from the pancreas in Mickey. The cellularity is mixed. The most prominent cellularity consists of neutrophils with scattered lymphocytes and rare macrophages. There are degenerate necrotic structures with mucoid material in the background of hemorrhage. There were rare epithelial tissue cells. Malignant characteristics are not identified.

## INTERPRETATION OF FINDINGS & FURTHER RECOMMENDATIONS

Pyogranulomatous inflammation and necrosis consistent with localized pancreatitis.

## COMMENTS

The cellularity in all of these excellent videos suggests the likelihood of a chronic necrotizing pancreatitis. Neutrophils and saponified fat are part of the process. There are no changes that would support sepsis or neoplasia. This inflammatory process appears to be affecting the surrounding omental tissue as well as the pancreas. This is likely due to release of enzymes into the surrounding tissue. Treatment for pancreatitis is encouraged. A guarded prognosis is warranted since this type of disease process can be difficult to treat.

## CYTOLOGY IMAGE

This is an image representing the prominent cellularity of neutrophils with scattered lymphocytes, necrotic debris, platelets and hemorrhage collected from the pancreatic aspirate in Mickey.



## PATIENT

Mickey Silverstein

## SPECIES

Feline

## BREED

DSH

## SEX

Spayed Female

## AGE

15 Years

## WEIGHT

14.3 lbs

## INTERPRETED BY

Dr. Lawrence McGill,  
DVM, Ph.D., Diplomate,  
ACVP

## IMAGING PERFORMED BY

Nick Pizzemento

## HOSPITAL NAME

Central Veterinary  
Hospital

## REFERRING VET

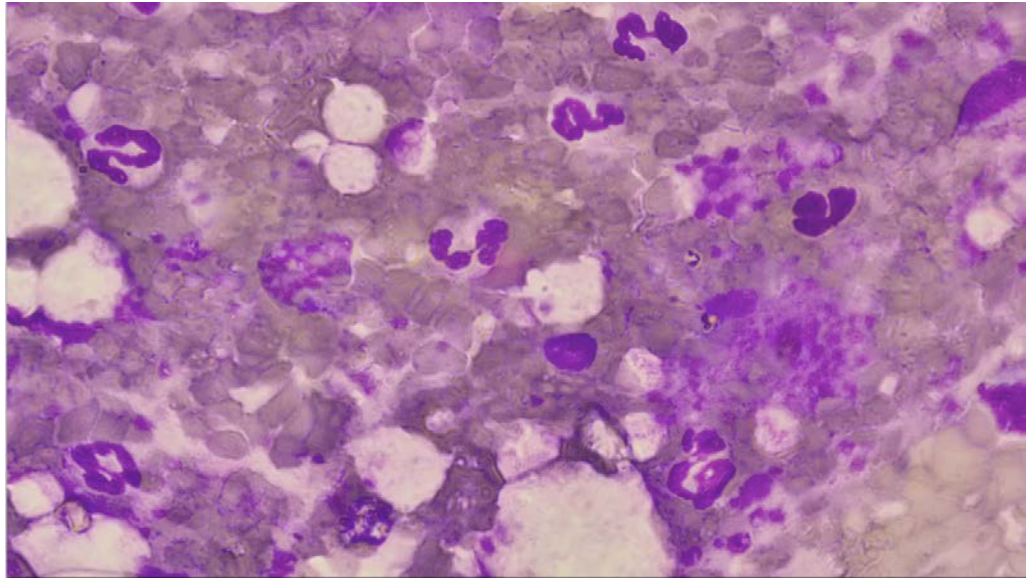
Dr. Michel Hardaker

## INVOICE

74559

## DATE

4/17/26



The information and recommendations provided are based on the images presented by the referring veterinarian/sonographer. No evaluation can be communicated regarding pathology that was not visible in the image/video clips provided.

Thank you for this referral. If the clinical or image interpretation does not parallel your findings or if I can be of any further assistance please contact me.

**L.D. McGill, DVM, Ph.D., DACVP**

8288 Top of the World Dr. Cottonwood Heights, UT 84121

Cell: 801-865-1220 [Ldmcgill.vetpath@gmail.com](mailto:Ldmcgill.vetpath@gmail.com)