



PATIENT

Bingo Yelin

SPECIES

Feline

BREED

Domestic Shorthair

SEX

Spayed female

AGE

2 years

WEIGHT

8 lbs

INTERPRETED BY

Dr. Lawrence McGill,
DVM,Ph.D.,Diplomate,
ACVP

IMAGING PERFORMED BY

Christine LVT

HOSPITAL NAME

Rotterdam VH

REFERRING VET

Dr. Anna St Sir

INVOICE

74504

DATE

4/15/26

PRESENTING CLINICAL SIGNS

History: Sudden acute pain, can barely walk. Cranial mediastinal mass, enlarged spleen. On Ultrasound, chest mass, heteroechoic adjacent to the heart. Spleen is uniformly enlarged.

CYTOLOGY SUBMISSION

FNA of the spleen and chest mass were submitted

OBSERVATIONS

Spleen: Submitted are 2 excellent videos of excellent collections of cells from the spleen in Bingo. The cellularity is almost entirely round cells. The round cells have minimal cytoplasm and large irregular nuclei. Many of the nuclei are cleft. There are scattered small to intermediate lymphoid cells but the majority are large irregular atypical lymphoid cells with scattered mitotic figures.

Chest mass: Submitted are 5 excellent videos of excellent collections of cells from the chest mass in Bingo. The cellularity in this collection is very similar to the cellularity in the spleen. There are mainly round cells scattered throughout with many of the cells demonstrating large atypical lymphoid structures including large nuclei many of which are cleft. Mitotic figures were easily identified. There were scattered small to intermediate lymphoid cells but the majority of the cells are atypical lymphoid cells.

INTERPRETATION OF FINDINGS & FURTHER RECOMMENDATIONS

Spleen - Characteristic of high-grade lymphoma
Chest mass - Characteristic of high-grade lymphoma

COMMENTS

The cellularity in these two sites is identical and consists of high-grade lymphoma cells and both sites. There are minimal numbers of mature lymphoid cells. The mitotic index is quite high even in the cytology slides. Further evaluation to confirm the diagnosis may utilize PARR testing. These slides appear to have adequate numbers of cells to be appropriate for additional testing. An unfavorable prognosis is warranted in my opinion since there are two sites involved in an aggressive high-grade lymphoma. Some of these individuals will respond to chemotherapy for a period of time. The FeLV status of this cat should be evaluated.



PATIENT

Bingo Yelin

SPECIES

Feline

BREED

Domestic Shorthair

SEX

Spayed female

AGE

2 years

WEIGHT

8 lbs

INTERPRETED BY

Dr. Lawrence McGill,
DVM, Ph.D., Diplomate,
ACVP

IMAGING PERFORMED BY

Christine LVT

HOSPITAL NAME

Rotterdam VH

REFERRING VET

Dr. Anna St Sir

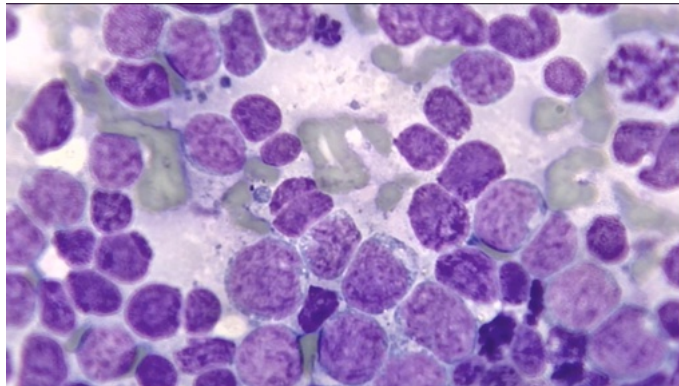
INVOICE

74504

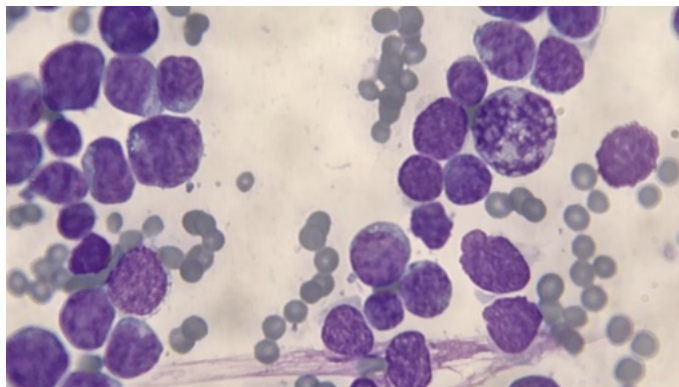
DATE

4/15/26

CYTOLOGY IMAGE



This is an image of cells collected from the spleen in Bingo. Note the large numbers of large cells with a mitotic figure in the upper right.



This is an image of cells collected from the chest mass in Bingo. Note the similarity between the lymphoid cells in the spleen. There is a mitotic figure in the upper right in this field as well. Compare the large lymphoid cells to the small mature lymphoid cells.

The information and recommendations provided are based on the images presented by the referring veterinarian/sonographer. No evaluation can be communicated regarding pathology that was not visible in the image/video clips provided.

Thank you for this referral. If the clinical or image interpretation does not parallel your findings or if I can be of any further assistance please contact me.

L.D. McGill, DVM, Ph.D., DACVP

8288 Top of the World Dr. Cottonwood Heights, UT 84121

Cell: 801-865-1220 Ldmcgill.vetpath@gmail.com