



## PATIENT

Bailey Richter

## SPECIES

Canine

## BREED

Poodle

## SEX

Spayed female

## AGE

13 years

## WEIGHT

50 lbs

## INTERPRETED BY

Dr. Lawrence McGill,  
DVM,Ph.D.,Diplomate,  
ACVP

## IMAGING PERFORMED BY

Dr. Waffle

## HOSPITAL NAME

Torch Lake VC

## REFERRING VET

Dr. Waffle

## INVOICE

74484

## DATE

4/15/26

## PRESENTING CLINICAL SIGNS

History: -plural effusion.

## CYTOLOGY SUBMISSION

Ultrasound-guided aspirated fluid was submitted

## OBSERVATIONS

Pleural fluid: Submitted are 13 slightly out of focus images of cells collected from the pleural fluid in Bailey. There is a background of red blood cells supporting moderate hemodilution but this is probably what is occurring in the pleural cavity. There are large numbers of nucleated cells, many of which are neutrophils with good numbers of lymphocytes, scattered eosinophils and one or two images of reactive mesothelial cells. The lymphoid cells are mainly small lymphocytes. In several fields, the neutrophils are the most prominent cellularity.

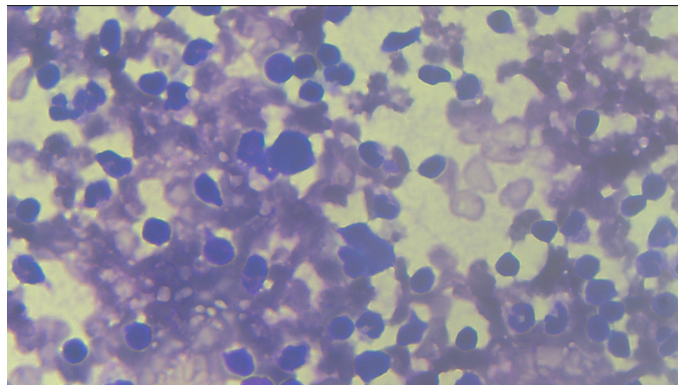
## INTERPRETATION OF FINDINGS & FURTHER RECOMMENDATIONS

Pleural fluid - Chronic suppurative pleuritis with increased numbers of lymphocytes.

## COMMENTS

The cellular changes support inflammation with some increased numbers of neutrophils. With the small mature lymphocytes, I am concerned about the possibility of a thymoma but certainly cannot make that diagnosis. This inflammatory response easily could be the result of inflammation in the lungs draining into the pleural cavity. Further evaluation to determine whether there is a mass in the thoracic cavity is encouraged. There is definitely inflammation which could be primary or secondary. Eosinophils can be seen with thymoma cases. This is a lot of cells in the pleural cavity and thus there is something occurring but the specific source has not been identified. Again evaluation for a mass in the thoracic cavity is encouraged.

## CYTOLOGY IMAGE





## PATIENT

Bailey Richter

This is an image demonstrating a representative field of cells collected from the pleural cavity in Bailey. There appear to be large numbers of lymphocytes and neutrophils with an eosinophil or two in this collection. Note the slightly hazy pattern which suggests that the image is slightly out of focus.

## SPECIES

Canine

## BREED

Poodle

## SEX

Spayed female

**The information and recommendations provided are based on the images presented by the referring veterinarian/sonographer. No evaluation can be communicated regarding pathology that was not visible in the image/video clips provided.**

Thank you for this referral. If the clinical or image interpretation does not parallel your findings or if I can be of any further assistance please contact me.

## AGE

13 years

**L.D. McGill, DVM, Ph.D., DACVP**

8288 Top of the World Dr. Cottonwood Heights, UT 84121

## WEIGHT

50 lbs

Cell: 801-865-1220 [Ldmcgill.vetpath@gmail.com](mailto:Ldmcgill.vetpath@gmail.com)

## INTERPRETED BY

Dr. Lawrence McGill,  
DVM, Ph.D., Diplomate,  
ACVP

## IMAGING PERFORMED BY

Dr. Waffle

## HOSPITAL NAME

Torch Lake VC

## REFERRING VET

Dr. Waffle

## INVOICE

74484

## DATE

4/15/26