



PATIENT

Zara Salome

SPECIES

Canine

BREED

Doberman

SEX

Spayed Female

AGE

12 Years

WEIGHT

34 kg

INTERPRETED BY

Dr. Lawrence McGill,
DVM, Ph.D., Diplomate,
ACVP

IMAGING PERFORMED BY

Dr. Iftikhar Raza

HOSPITAL NAME

Pawsitive Veterinary
Clinic Dubai Silicon
Oasis

REFERRING VET

Dr. Iftikhar Raza

INVOICE

15106

DATE

04/14/26

PRESENTING CLINICAL SIGNS

11-year-old dog presented with behavioral changes characterized by pacing and excessive barking, suggestive of anxiety. The owner reports a chronic history of polyuria and polydipsia. Additionally, the dog exhibits frequent head shaking and scratching. Dermatological concerns include multiple small epidermal collarettes noted on the skin of the limbs. Physical Examination reveals Peripheral edema in the distal limbs, as well as along the ventral abdomen. The abdomen is distended and firm on palpation.

Ultrasound examination revealed large heterogenous mid abdomen mass most likely originating from spleen, also copious amount of pleural effusions were present which were drained (almost 2 liters), fluid removed was watery slight pinkish white color.

Microscopic evaluation of pleural effusion was performed and images submitted for evaluation.

Abnormal PE/Chem/CBC/UA Results: Normal CBC elevated ALKP - 392 U/L normal range 23 - 212 U/L Normal TT4 Resting cortisol - 15.17 µg/dL

CYTOLOGY SUBMISSION

FNA of abdominal fluid was submitted.

OBSERVATIONS

Abdominal fluid: Submitted are 39 very good images of excellent collections of cells from the abdominal fluid in Zara. The cellularity is mixed with large numbers of macrophages or reactive mesothelial cells. Many of these cells have vacuolated cytoplasm and are phagocytosing different structures including red blood cells. These cells are interspersed with neutrophils and small mature lymphocytes. Occasional crystalline structures are found in some of the cells and free in the fluid. There is no suggestion of malignancy in this collection.

INTERPRETATION OF FINDINGS & FURTHER RECOMMENDATIONS

Abdominal fluid - Pyogranulomatous inflammation with apparent saponification of fat.

COMMENTS

The cellularity in this collection supports a severe inflammatory process. This inflammatory process could be the result of pancreatitis and releasing pancreatic enzymes into the abdominal cavity and thus digesting fat tissue. It could be due to other types of inflammatory processes, but it does not appear to be septic and is not neoplastic. This is a severe chronic inflammatory process related to some type of inflammation in the abdominal cavity. A guarded prognosis is warranted until the underlying process causing inflammation can be confirmed.

CYTOLOGY IMAGE

This is an image of a field of cells collected from the abdominal fluid in Zara. Note the prominent macrophages which are showing vacuolated cytoplasm and hemosiderin in the cytoplasm with scattered neutrophils and lymphocytes and no suggestion of neoplasia. There are small crystalline structures in the collection suggesting the possibility of saponification of fat.



PATIENT

Zara Salome

SPECIES

Canine

BREED

Doberman

SEX

Spayed Female

AGE

12 Years

WEIGHT

34 kg

INTERPRETED BY

Dr. Lawrence McGill,
DVM, Ph.D., Diplomate,
ACVP

IMAGING PERFORMED BY

Dr. Iftikhar Raza

HOSPITAL NAME

Pawsitive Veterinary
Clinic Dubai Silicon
Oasis

REFERRING VET

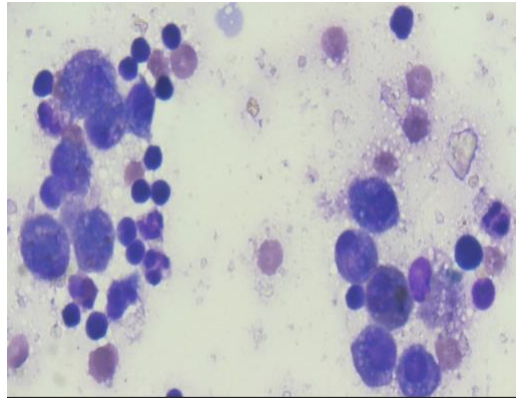
Dr. Iftikhar Raza

INVOICE

15106

DATE

04/14/26



The information and recommendations provided are based on the images presented by the referring veterinarian/sonographer. No evaluation can be communicated regarding pathology that was not visible in the image/video clips provided.

Thank you for this referral. If the clinical or image interpretation does not parallel your findings or if I can be of any further assistance please contact me.

L.D. McGill, DVM, Ph.D., DACVP

8288 Top of the World Dr. Cottonwood Heights, UT 84121

Cell: 801-865-1220 Ldmcgill.vetpath@gmail.com