



PATIENT

Charlie Olena Busol

SPECIES

Canine

BREED

Miniature Pinscher

SEX

Male

AGE

7 years

WEIGHT

3.7 kg

INTERPRETED BY

Dr. Lawrence McGill,
DVM,Ph.D.,Diplomate,
ACVP

IMAGING PERFORMED BY

Dr. Muhannad

HOSPITAL NAME

Pawsitive Veterinary
Clinic Dubai Silicon
Oasis

REFERRING VET

Dr. Muhannad

INVOICE

74006

DATE

4/1/26

PRESENTING CLINICAL SIGNS

- Charlie was presented with an history of a small ,pea sized swelling at the base of the right ear.The mass has been present for almost a year and has not increased in size. fine needle aspiration of the mass was performed and submitted for evaluation.

CYTOLOGY SUBMISSION

FNA of the mass on the base of the ear was submitted

OBSERVATIONS

Mass at the base of the ear: Submitted are 14 excellent images of excellent collections of cells from the mass at the base of the right ear on Charlie. The cellularity is consistent through the images. It consists of mature keratinized cells with secondary debris. There were scattered granular structures but they were nonspecific. There is no suggestion of malignancy or infection. The keratinized debris was present in all of the images in different forms.

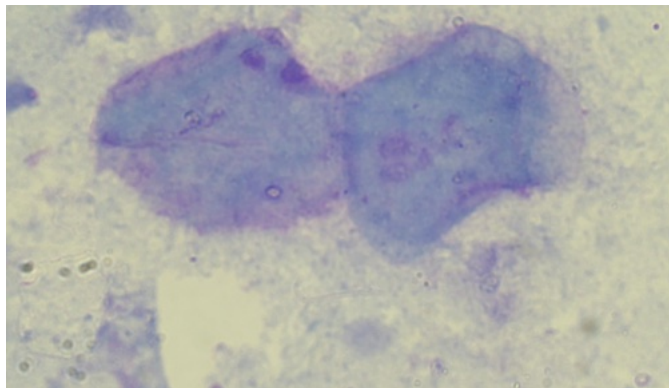
INTERPRETATION OF FINDINGS & FURTHER RECOMMENDATIONS

Mass at the base of the right ear - Keratinized debris consistent with a keratinized cyst.

COMMENTS

The cellularity in this collection is very characteristic of a keratinized cystic structure. There is no suggestion of malignancy in the collection but there is prominent keratinized material. This is a good collection of that type of cystic process. Excision of the lesion is encouraged since this growth will not go away on its own. Narrow margins are adequate. A good if completely excised prognosis is warranted.

CYTOLOGY IMAGE



This is an image of keratinized cells collected from the mass at the base of the right ear on Charlie. Note the fact that these cells are keratinized but they do not have nuclei. Irregular debris is present around this cellularity.



PATIENT

Charlie Olena Busol

SPECIES

Canine

BREED

Miniature Pinscher

SEX

Male

AGE

7 years

WEIGHT

3.7 kg

INTERPRETED BY

Dr. Lawrence McGill,
DVM, Ph.D., Diplomate,
ACVP

IMAGING PERFORMED BY

Dr. Muhannad

HOSPITAL NAME

Pawsitive Veterinary
Clinic Dubai Silicon
Oasis

REFERRING VET

Dr. Muhannad

INVOICE

74006

DATE

4/1/26

The information and recommendations provided are based on the images presented by the referring veterinarian/sonographer. No evaluation can be communicated regarding pathology that was not visible in the image/video clips provided.

Thank you for this referral. If the clinical or image interpretation does not parallel your findings or if I can be of any further assistance please contact me.

L.D. McGill, DVM, Ph.D., DACVP

8288 Top of the World Dr. Cottonwood Heights, UT 84121

Cell: 801-865-1220 Ldmcgill.vetpath@gmail.com