



PATIENT

C Vlad Veronique Van
Nerum

SPECIES

Canine

BREED

Belgian Malinois

SEX

Male

AGE

19 weeks

WEIGHT

14.5 kg

INTERPRETED BY

Dr. Lawrence McGill,
DVM,Ph.D.,Diplomate,
ACVP

IMAGING PERFORMED BY

Dr. Rizwan

HOSPITAL NAME

Kings VC LLC Dubai

REFERRING VET

Dr. Rizwan

INVOICE

72234

DATE

3/5/26

PRESENTING CLINICAL SIGNS

- Owner noticed around 5cm lump on right axillary region. Size is not increasing. Lump is mobile and painless. FNA is performed and images are attached.

CYTOLOGY SUBMISSION

FNA of skin mass was submitted

OBSERVATIONS

Skin mass from the axilla: Submitted are 15 very good images of very good to excellent collections of cells from the skin mass in the right axilla on Vlad. The cellularity is consistent throughout many of these images. There are many round cells, many of which contain metachromatic to purple granules or are irregularly granulated throughout the collection. There is a background of granular material that appears to be the same granules in these cells. These granules support mast cells. Scattered other inflammatory cells are present.

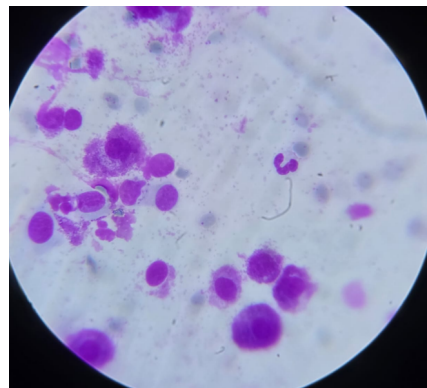
INTERPRETATION OF FINDINGS & FURTHER RECOMMENDATIONS

Skin mass from the right axilla - Mast cell tumor.

COMMENTS

This is a very good collection of mast cells from this tumor process in the right axilla of Vlad. This cellularity is characteristic of a mast cell tumor. It is not common but I have seen mast cell tumors in very young dogs. This lesion should be completely excised by wide margins if at all possible. Mast cell tumors are difficult to predict and thus a guarded prognosis is warranted in this dog. If additional mast cell tumors appear in the near future, then Vlad should be monitored for the potential of internal mast cell disease. This is an excellent collection of cells in many of the images.

CYTOLOGY IMAGE



This is an image demonstrating several mast cells with scattered eosinophils and a background of granules from this mast cell tumor in the skin of Vlad.



PATIENT

C Vlad Veronique Van
Nerum

SPECIES

Canine

BREED

Belgian Malinois

SEX

Male

AGE

19 weeks

WEIGHT

14.5 kg

INTERPRETED BY

Dr. Lawrence McGill,
DVM, Ph.D., Diplomate,
ACVP

IMAGING PERFORMED BY

Dr. Rizwan

HOSPITAL NAME

Kings VC LLC Dubai

REFERRING VET

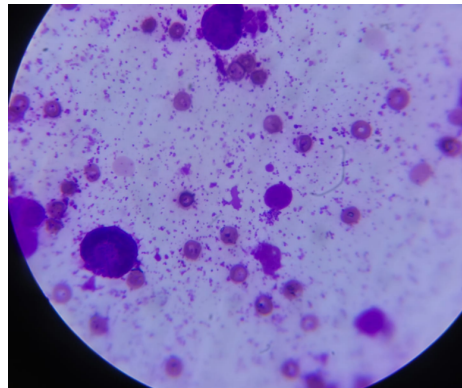
Dr. Rizwan

INVOICE

72234

DATE

3/5/26



This is a second image demonstrating well granulated mast cells with a background of mast cell granules interspersed throughout the red cells from the skin mass aspirated from Vad.

The information and recommendations provided are based on the images presented by the referring veterinarian/sonographer. No evaluation can be communicated regarding pathology that was not visible in the image/video clips provided.

Thank you for this referral. If the clinical or image interpretation does not parallel your findings or if I can be of any further assistance please contact me.

L.D. McGill, DVM, Ph.D., DACVP

8288 Top of the World Dr. Cottonwood Heights, UT 84121

Cell: 801-865-1220 Ldmcgill.vetpath@gmail.com