



PATIENT

Amici McPherson

SPECIES

Feline

BREED

Domestic Shorthair

SEX

Neutered male

AGE

13 years

WEIGHT

11 lbs

INTERPRETED BY

Dr. Lawrence McGill,
DVM,Ph.D.,Diplomate,
ACVP

IMAGING PERFORMED BY

Erin, LVT

HOSPITAL NAME

Rotterdam VH

REFERRING VET

Dr. Anna St Sir

INVOICE

72212

DATE

3/4/26

PRESENTING CLINICAL SIGNS

- On ultrasound, right kidney is deformed. Ultrasound guided FNA taken.

CYTOLOGY SUBMISSION

FNA of the kidney was submitted

OBSERVATIONS

Kidney; Submitted are 5 excellent videos and 2 excellent images of cells collected from the kidney in Amichi. The cellularity is consistent through all of the images and videos. There is a background of red blood cells but there are good aggregates of cells that have slightly irregular nuclei and a vacuolated to granulated cytoplasm. This is consistent through all of these videos and images. The granularity of the cytoplasm is not specific and causes concern about the specific source of the cells.

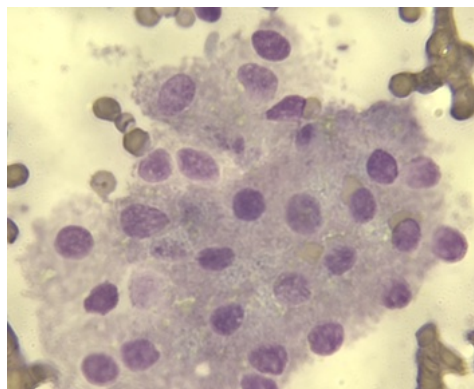
INTERPRETATION OF FINDINGS & FURTHER RECOMMENDATIONS

Kidney - Strongly suggestive of a neoplastic process and probable carcinoma.

COMMENTS

The cellularity is so consistent throughout all of these images and videos that it must be some type of a neoplastic process. A carcinoma seems most likely. I am concerned about the possibility of an adrenal gland carcinoma or some type of renal carcinoma. Biopsy and collection of cells will be required to confirm the underlying source but all of the changes in this collection strongly suggest neoplasia and probable carcinoma. A guarded to unfavorable prognosis is warranted due to this proliferative process.

CYTOLOGY IMAGE



This image demonstrates a group of cells collected from the kidney in Amici. Note the aggregation of granules and small vacuoles in the cells. There is also some pigment which could be from many different tumor cell types.

The information and recommendations provided are based on the images presented by the referring veterinarian/sonographer. No evaluation can be communicated regarding pathology that was not visible in the image/video clips provided.



PATIENT

Amici McPherson

SPECIES

Feline

BREED

Domestic Shorthair

SEX

Neutered male

AGE

13 years

WEIGHT

11 lbs

INTERPRETED BY

Dr. Lawrence McGill,
DVM, Ph.D., Diplomate,
ACVP

IMAGING PERFORMED BY

Erin, LVT

HOSPITAL NAME

Rotterdam VH

REFERRING VET

Dr. Anna St Sir

INVOICE

72212

DATE

3/4/26

Thank you for this referral. If the clinical or image interpretation does not parallel your findings or if I can be of any further assistance please contact me.

L.D. McGill, DVM, Ph.D., DACVP

8288 Top of the World Dr. Cottonwood Heights, UT 84121

Cell: 801-865-1220 Ldmcgill.vetpath@gmail.com