



PATIENT

Sally Jones

SPECIES

Canine

BREED

Cane Corso Mix

SEX

Spayed Female

AGE

~7 Years

WEIGHT

100.2 Pounds

INTERPRETED BY

Dr. Lawrence McGill,
DVM, Ph.D., Diplomate,
ACVP

IMAGING PERFORMED BY

Erin, LVT/Christine,
LVT

HOSPITAL NAME

Rotterdam VH

REFERRING VET

Dr. Sarah Kopa

INVOICE

36426

DATE

3/29/26

PRESENTING CLINICAL SIGNS

- Newly adopted dog
- presented for exam to establish care
- 1 cm firm dermal mass on digit 3 of LH, ulcerated
- FNA taken for pathology review

CYTOLOGY SUBMISSION

FNA of digital mass.

OBSERVATIONS

Submitted are 6 excellent images and one excellent video of cells collected from the dermal mass on Sally. The cells appear to be aggregated in irregular patterns with mild anisokaryosis and prominent anisocytosis. In one of the images, there is a suggestion of chainlike patterns of growth. There is mild secondary inflammation, but the major cellularity consists of this proliferation of irregular cells that are packeted.

INTERPRETATION OF FINDINGS & FURTHER RECOMMENDATIONS

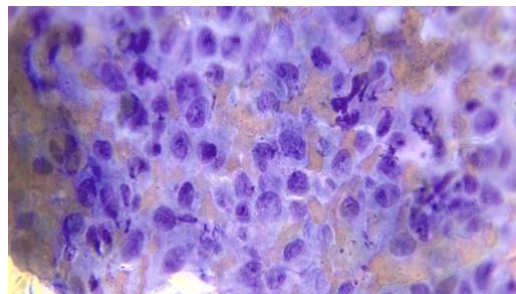
Digital mass - Suggestive of basal cell tumor due to epithelial cell proliferation.

COMMENTS

The cellularity in this collection is suggestive of a proliferative process, and it appears to be epithelial in nature. Excision of the mass to confirm the process is encouraged. With the cellularity, it appears to be benign cytologically, but this will require a follow-up biopsy to confirm. My concern is that this is a location that is difficult to do surgery, but you will know what to do and hopefully margins do not have to be wide. I am expecting a good if completely excised prognosis in this region.

CYTOLOGY IMAGE

This is an image of aggregated cells collected from the digital mass on Sally. Note the prominent anisokaryosis in these cells and the close aggregation.



The information and recommendations provided are based on the images presented by the referring veterinarian/sonographer. No evaluation can be communicated regarding pathology that was not visible in the image/video clips provided.



PATIENT

Sally Jones

SPECIES

Canine

BREED

Cane Corso Mix

SEX

Spayed Female

AGE

~7 Years

WEIGHT

100.2 Pounds

INTERPRETED BY

Dr. Lawrence McGill,
DVM, Ph.D., Diplomate,
ACVP

**IMAGING
PERFORMED BY**

Erin, LVT/Christine,
LVT

HOSPITAL NAME

Rotterdam VH

REFERRING VET

Dr. Sarah Kopa

INVOICE

36426

DATE

3/29/26

Thank you for this referral. If the clinical or image interpretation does not parallel your findings or if I can be of any further assistance please contact me.

L.D. McGill, DVM, Ph.D., DACVP

8288 Top of the World Dr. Cottonwood Heights, UT 84121

Cell: 801-865-1220 Ldmcgill.vetpath@gmail.com