



## PATIENT

Barney Barney

## SPECIES

Canine

## BREED

Golden Retriever

## SEX

Neutered male

## AGE

2 years

## WEIGHT

41 lbs

## INTERPRETED BY

Dr. Lawrence McGill,  
DVM, Ph.D., Diplomate,  
ACVP

## IMAGING PERFORMED BY

Dr. Muhannad

## HOSPITAL NAME

Pawsiitive Veterinary  
Clinic Dubai Silicon  
Oasis

## REFERRING VET

73493

## INVOICE

73493

## DATE

3/17/26

## PRESENTING CLINICAL SIGNS

- Small lump raised from his back one month ago not getting big 0.5 cm x 0.5 cm cutaneous lump on the left dorsum caudally
- FNA sample was collected from lump

## CYTOLOGY SUBMISSION

FNA of the left dorsal lump was submitted

## OBSERVATIONS

Left Dorsal Lump: Submitted are 17 very good images of cells and material collected from the left dorsal lump on Barney. There are scattered keratinized cells interspersed with protein, RBCs and debris. Nucleated cells are rare. There was one macrophage in the collection. Malignant or septic changes are not identified.

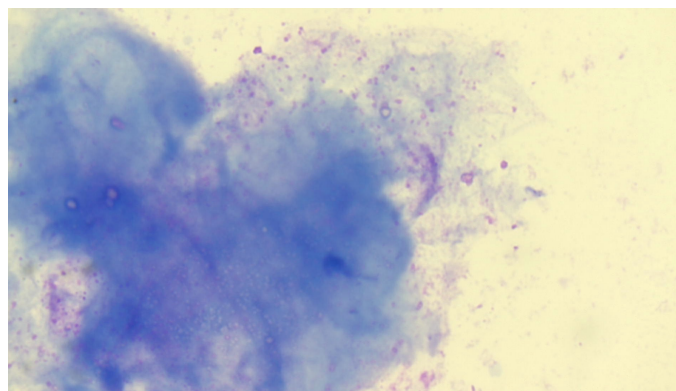
## INTERPRETATION OF FINDINGS & FURTHER RECOMMENDATIONS

Left Dorsal lump - Keratinized cells with fluid.

## COMMENTS

There are very few nucleated cells. The most common cellularity is keratinized cells. This suggests a keratinized cyst with secondary edema. There is no suggestion of neoplasia or infection. Draining the cyst may help but I suspect that it will not go away without surgery and removal. Some of the reaction is likely secondary to trauma and vascular leakage. If it is traumatized more, the lesion may become inflamed and grow more. Thus removal is suggested to eliminate that potential. A good if completely excised prognosis is expected.

## CYTOLOGY IMAGE



This is an image showing keratinized cells with surrounding protein and debris collected from the left dorsal lump on Barney.



## PATIENT

Barney Barney

## SPECIES

Canine

## BREED

Golden Retriever

## SEX

Neutered male

## AGE

2 years

## WEIGHT

41 lbs

## INTERPRETED BY

Dr. Lawrence McGill,  
DVM, Ph.D., Diplomate,  
ACVP

## IMAGING PERFORMED BY

Dr. Muhannad

## HOSPITAL NAME

Pawsitive Veterinary  
Clinic Dubai Silicon  
Oasis

## REFERRING VET

73493

## INVOICE

73493

## DATE

3/17/26

The information and recommendations provided are based on the images presented by the referring veterinarian/sonographer. No evaluation can be communicated regarding pathology that was not visible in the image/video clips provided.

Thank you for this referral. If the clinical or image interpretation does not parallel your findings or if I can be of any further assistance please contact me.

**L.D. McGill**, DVM, Ph.D., DACVP

8288 Top of the World Dr. Cottonwood Heights, UT 84121

Cell: 801-865-1220 [Ldmcgill.vetpath@gmail.com](mailto:Ldmcgill.vetpath@gmail.com)