



PATIENT

Saeed Saeed

SPECIES

Feline

BREED

Domestic Shorthair

SEX

Male

AGE

1 year

WEIGHT

4.1 kg

INTERPRETED BY

Dr. Lawrence McGill,
DVM,Ph.D.,Diplomate,
ACVP

IMAGING PERFORMED BY

Dr. Muhannad

HOSPITAL NAME

Pawsitive Veterinary
Clinic Dubai Silicon
Oasis

REFERRING VET

Dr. Muhannad

INVOICE

73391

DATE

3/11/26

PRESENTING CLINICAL SIGNS

- During the surgical Procedure, noticed that his pancreases appeared inflamed and also abdominal lymph nodes were also enlarge
- FNA sample was collected from abdominal lymph node during the surgery

CYTOLOGY SUBMISSION

FNA of the lymph node was submitted

OBSERVATIONS

Lymph node: Submitted are 22 very good images of minimal numbers of nucleated cells collected from the lymph node in Saeed. There is a background of red blood cells in all the images with scattered nucleated cells. Most of the nucleated cells are small mature lymphocytes or intermediate lymphocytes. There are rare neutrophils. The nucleated cellularity again is very minimal.

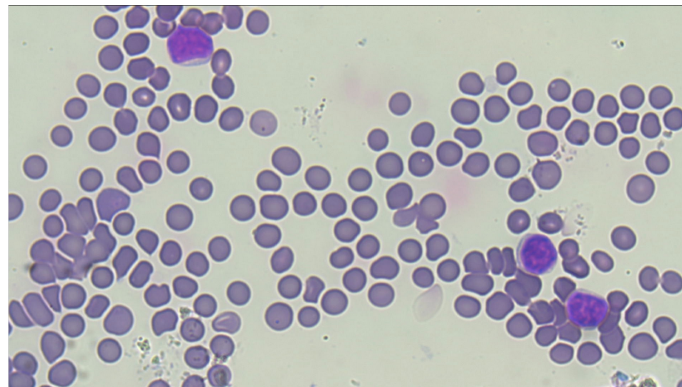
INTERPRETATION OF FINDINGS & FURTHER RECOMMENDATIONS

Lymph node - Minimal nucleated cellularity with suggestions of reactive lymph node and mild suppurative lymphadenitis.

COMMENTS

The cellularity in this collection is minimal as described and thus the potential of being able to provide a diagnostic interpretation is limited. The cellularity on the images suggests a reactive lymph node and mild suppurative lymphadenitis. This could be secondary to pancreatitis or some other process. Occasionally young cats will have enlarged lymph nodes that are reactive and not pathologic. A guarded prognosis is warranted since the underlying process has not been confirmed.

CYTOLOGY IMAGE



This is an image demonstrating one of the more cellular images with large numbers of red blood cells and interspersed intermediate sized lymphocytes collected from the mesenteric lymph node in Saeed.



PATIENT

Saeed Saeed

SPECIES

Feline

BREED

Domestic Shorthair

SEX

Male

AGE

1 year

WEIGHT

4.1 kg

INTERPRETED BY

Dr. Lawrence McGill,
DVM, Ph.D., Diplomate,
ACVP

IMAGING PERFORMED BY

Dr. Muhannad

HOSPITAL NAME

Pawsitive Veterinary
Clinic Dubai Silicon
Oasis

REFERRING VET

Dr. Muhannad

INVOICE

73391

DATE

3/11/26

The information and recommendations provided are based on the images presented by the referring veterinarian/sonographer. No evaluation can be communicated regarding pathology that was not visible in the image/video clips provided.

Thank you for this referral. If the clinical or image interpretation does not parallel your findings or if I can be of any further assistance please contact me.

L.D. McGill, DVM, Ph.D., DACVP

8288 Top of the World Dr. Cottonwood Heights, UT 84121

Cell: 801-865-1220 Ldmcgill.vetpath@gmail.com