



PATIENT

Pupu Guo

SPECIES

Canine

BREED

Golden Retriever

SEX

Female

AGE

4 years

WEIGHT

50 kg

INTERPRETED BY

Dr. Lawrence McGill,
DVM,Ph.D.,Diplomate,
ACVP

IMAGING PERFORMED BY

Dr. Junaid

HOSPITAL NAME

Pawsitive Veterinary
Clinic Dubsi Silicon
Oasis

REFERRING VET

Dr. Junaid

INVOICE

71327

DATE

2/6/26

PRESENTING CLINICAL SIGNS

4yrs old female Golden retriever presented with the complaint of 3-4cm subcutaneous Mass/Lump on right hindleg. The lump is moveable, painless and with no itching. Owner observed 3-4 days ago and have no idea if the size is increasing or not. Sample was taken through FNA for cytology and slides were observed on 100X.

CYTOLOGY SUBMISSION

FNA of subcutaneous mass was submitted

OBSERVATIONS

Subcutaneous mass: Submitted are 18 excellent images of very good collections of cells from the subcutaneous mass on Pupu. The collection includes large numbers of keratinized cells that do not have nuclei. Proteinaceous material and degenerate debris are present in the background. Very few nucleated cells are present but these cells in the cyst confirm the process. There is no suggestion of malignancy or inflammation in the collection but there is a collection of large numbers of keratinized cells.

INTERPRETATION OF FINDINGS & FURTHER RECOMMENDATIONS

Subcutaneous mass - Keratinized cyst consistent with epidermal inclusion cyst or follicular cyst.

COMMENTS

This is a characteristic collection of keratinized cells from a keratinized cyst. The lesion has not ruptured at this time and thus excision will likely eliminate the process and is really the only means for therapy. The mass should be excised since rupture of the lesion will cause rather severe inflammation. Keratinized cellularity is extremely irritating to the body. Again there is no suggestion of infection or neoplastic tissue in this very good collection. A good if completely excised prognosis is warranted in this case.



PATIENT

Pupu Guo

SPECIES

Canine

BREED

Golden Retriever

SEX

Female

AGE

4 years

WEIGHT

50 kg

INTERPRETED BY

Dr. Lawrence McGill,
DVM, Ph.D., Diplomate,
ACVP

IMAGING PERFORMED BY

Dr. Junaid

HOSPITAL NAME

Pawsitive Veterinary
Clinic Dubsi Silicon
Oasis

REFERRING VET

Dr. Junaid

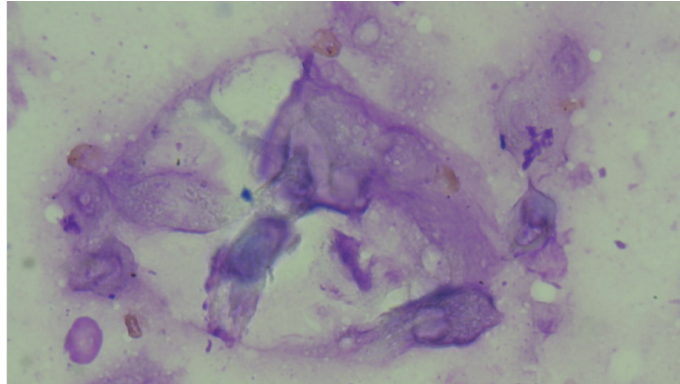
INVOICE

71327

DATE

2/6/26

CYTOLOGY IMAGE



This is an image of keratinized cells and material expected in a keratinized cyst in the subcutaneous region on Pupu.

The information and recommendations provided are based on the images presented by the referring veterinarian/sonographer. No evaluation can be communicated regarding pathology that was not visible in the image/video clips provided.

Thank you for this referral. If the clinical or image interpretation does not parallel your findings or if I can be of any further assistance please contact me.

L.D. McGill, DVM, Ph.D., DACVP

8288 Top of the World Dr. Cottonwood Heights, UT 84121

Cell: 801-865-1220 Ldmcgill.vetpath@gmail.com