



PATIENT

Charlie Buttons Buzzo

SPECIES

Canine

BREED

Mix

SEX

Neutered male

AGE

12 years

WEIGHT

62 lbs

INTERPRETED BY

Dr. Lawrence McGill,
DVM,Ph.D.,Diplomate,
ACVP

IMAGING PERFORMED BY

Christine LVT

HOSPITAL NAME

Rotterdam VH

REFERRING VET

Dr. Scarpinato

INVOICE

71667

DATE

2/18/26

PRESENTING CLINICAL SIGNS

- RF digit has firm, ulcerated mass on medial aspect- 1.38cm x 2.3cm.

CYTOLOGY SUBMISSION

FNA of the foot mass were submitted

OBSERVATIONS

Foot mass: Submitted are 2 excellent videos and 6 excellent images of excellent collections of cells from the foot mass on Charlie Buttons. The cellularity is consistent throughout the images and the videos. The cells are vacuolated and slightly granulated with rounded nuclei and rounded cytoplasm. The cells are aggregated to the point that the cytoplasmic borders are not consistent. There is secondary inflammation in some of the images. Malignant characteristics are not identified but this is a proliferative benign process.

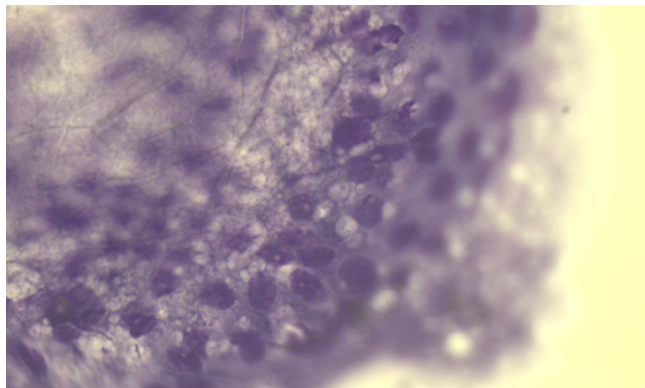
INTERPRETATION OF FINDINGS & FURTHER RECOMMENDATIONS

Footman mass - Characteristic of sebaceous gland adenoma.

COMMENTS

The cellularity is essentially diagnostic for a sebaceous gland proliferative process and it is most likely a sebaceous gland adenoma. I did not identify any malignant characteristics. There is some secondary inflammation. Excision of the mass will likely result in a favorable prognosis. These growths may occur in other sites in the skin. This area can be difficult for surgery but wide excision is not necessary to eliminate these masses.

CYTOLOGY IMAGE



This is an image of a group of vacuolated cells collected from the foot mass on Charlie Buttons. Note the vacuolization of the cells and the rather uniform pattern of the nuclei.

The information and recommendations provided are based on the images presented by the referring veterinarian/sonographer. No evaluation can be communicated regarding pathology



PATIENT

Charlie Buttons Buzzo

SPECIES

Canine

BREED

Mix

SEX

Neutered male

AGE

12 years

WEIGHT

62 lbs

INTERPRETED BY

Dr. Lawrence McGill,
DVM, Ph.D., Diplomate,
ACVP

IMAGING PERFORMED BY

Christine LVT

HOSPITAL NAME

Rotterdam VH

REFERRING VET

Dr. Scarpinato

INVOICE

71667

DATE

2/18/26

that was not visible in the image/video clips provided.

Thank you for this referral. If the clinical or image interpretation does not parallel your findings or if I can be of any further assistance please contact me.

L.D. McGill, DVM, Ph.D., DACVP

8288 Top of the World Dr. Cottonwood Heights, UT 84121

Cell: 801-865-1220 Ldmcgill.vetpath@gmail.com