



PATIENT

Jasper Marcoux

SPECIES

Feline

BREED

Domestic Longhair

SEX

Neutered male

AGE

9 years

WEIGHT

10.1 lbs

INTERPRETED BY

Dr. Lawrence McGill,
DVM, Ph.D., Diplomate,
ACVP

IMAGING PERFORMED BY

Dr. Karen Ebersole
DVM, DABVP

HOSPITAL NAME

Scanvet

REFERRING VET

Dr. McGarvey

INVOICE

71610

DATE

2/16/26

PRESENTING CLINICAL SIGNS

- Weight loss noted at annual exam. Hypercalcemia on BW. MSU Hypercalcemia panel was inconclusive. Spleen FNA was obtained
- PE: BCS 2-3/9, looks like used to be a much bigger cat, muscle wasting. CBC/Chem/T-4: Ca 12.1, SDMA 12 N, Creat 1.2 N. Rest WNL. MSU panel - iCa 1.6 H (1.0-1.4), PTH <0.50 L, PTHrP 0 (normal). Conclusion - Parathyroid independent hypercalcemia. AUS: renal cortical mineralizations/foci, splenomegaly (mild), pancreatitis, IBD/enteritis pattern in SI. No free fluid.

CYTOLOGY SUBMISSION

FNA of the spleen was submitted.

OBSERVATIONS

Spleen: Submitted are 8 excellent videos of minimal to moderate collections of nucleated cells in the slightly hemodiluted sample collected from Jasper. The cellularity is mixed. There are prominent neutrophils interspersed with small lymphocytes and plasma cells. There are rare macrophages and there are some aggregates of platelets but they are few. Malignant characteristics are not identified.

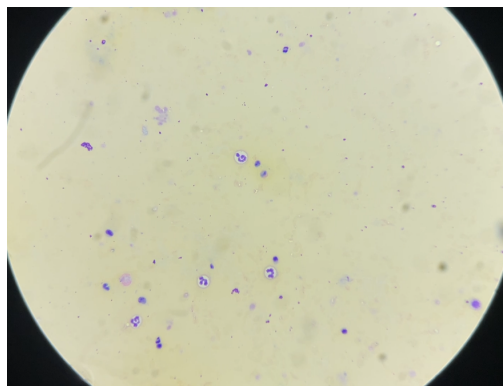
INTERPRETATION OF FINDINGS & FURTHER RECOMMENDATIONS

Spleen - Chronic suppurative splenitis with moderate hemodilution.

COMMENTS

The cellularity in this collection supports an inflammatory process within the spleen. This could be draining from the pancreatitis but I'm more suspicious about the possibility of FIP. An internal medicine colleague in Salt Lake came back from the ACVIM meeting last year saying that she was in a hall conference where they were saying in cats with intestinal signs and some inflammation, treatment for FIP seems to be positive. So this is something to think about in Jasper. I did not identify any changes that would support neoplasia but there certainly is prominent inflammation.

CYTOLOGY IMAGE



This is an image that demonstrates scattered neutrophils with scattered small lymphocytes and degenerate debris in a hemodiluted sample collected from Jasper. As you know it can be difficult collecting a non hemodiluted sample from the spleen.



PATIENT

Jasper Marcoux

SPECIES

Feline

BREED

Domestic Longhair

SEX

Neutered male

AGE

9 years

WEIGHT

10.1 lbs

INTERPRETED BY

Dr. Lawrence McGill,
DVM, Ph.D., Diplomate,
ACVP

IMAGING PERFORMED BY

Dr. Karen Ebersole
DVM, DABVP

HOSPITAL NAME

Scanvet

REFERRING VET

Dr. McGarvey

INVOICE

71610

DATE

2/16/26

The information and recommendations provided are based on the images presented by the referring veterinarian/sonographer. No evaluation can be communicated regarding pathology that was not visible in the image/video clips provided.

Thank you for this referral. If the clinical or image interpretation does not parallel your findings or if I can be of any further assistance please contact me.

L.D. McGill, DVM, Ph.D., DACVP

8288 Top of the World Dr. Cottonwood Heights, UT 84121

Cell: 801-865-1220 Ldmcgill.vetpath@gmail.com