



## PATIENT

Moxie Etscovitz

## SPECIES

Feline

## BREED

Domestic Shorthair

## SEX

Spayed female

## AGE

12 years

## WEIGHT

7 lbs

## INTERPRETED BY

Dr. Lawrence McGill,  
DVM, Ph.D., Diplomate,  
ACVP

## IMAGING PERFORMED BY

Dr. Karen Ebersole  
DVM, DABVP

## HOSPITAL NAME

Scanvet

## REFERRING VET

Dr. Balboni

## INVOICE

69355

## DATE

12/16/25

## PRESENTING CLINICAL SIGNS

History: Presented for hyporexia and weight loss on 12/4/2025. Started on Pred-L 5mg SID after initial BW and X-rays. Cytospin of peritoneal effusion.

PE: BCS 4/9. Thin muscle mass, bloated abdomen. Chem/CBC/T-4: X-ray - suspect ascites with "ground glass" appearance to mid-ventral abdomen. AUS (today)- large volume peritoneal effusion; enlarged, nodular and irregular pancreas; mesenteric lymphadenopathy - most consistent with infiltrative/metastatic pattern; variably sized heterogeneous nodules throughout mesentery.

## CYTOLOGY SUBMISSION

Abdominal fluid was submitted for evaluation

## OBSERVATIONS

Abdominal fluid: Submitted are 6 excellent videos of excellent collections of cells from the abdominal fluid in Moxie. The cellularity is mixed. There are large numbers of macrophages with foamy cytoplasm. Many of these cells are likely reactive mesothelial cells. Neutrophils are quite prominent throughout cellularity. Some of the macrophages have vacuolization in the cytoplasm. Malignant characteristics are not identified.

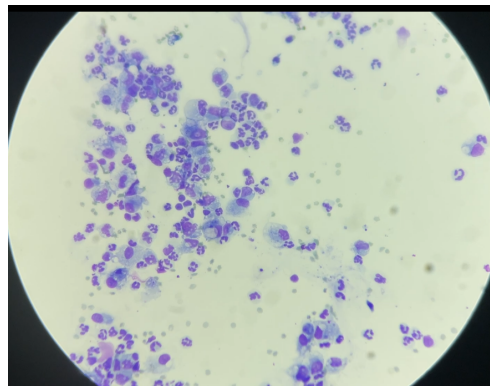
## INTERPRETATION OF FINDINGS & FURTHER RECOMMENDATIONS

Interpretation: Pyogranulomatous inflammation with markedly reactive mesothelial cells.

## COMMENTS

The cellularity is a characteristic severe inflammatory process. The inflammatory reaction is chronic in nature and could be the result of FIP or possibly severe chronic pancreatitis. I would not be surprised if both of these disease processes were involved. There is no suggestion of malignancy nor can I identify any other causes of disease including bacterial infection. Due to this severe inflammatory process, further evaluation for coronavirus infection and continued evaluation for pancreatitis is encouraged. A guarded to unfavorable prognosis is warranted with this severe inflammatory process.

## CYTOLOGY IMAGE



This is an image demonstrating large numbers of reactive macrophages and mesothelial cells interspersed with large numbers of neutrophils collected from the fluid in Moxie. This is an area of good concentration where the slides smear was stopped.



## PATIENT

Moxie Etscovitz

## SPECIES

Feline

## BREED

Domestic Shorthair

## SEX

Spayed female

## AGE

12 years

## WEIGHT

7 lbs

## INTERPRETED BY

Dr. Lawrence McGill,  
DVM, Ph.D., Diplomate,  
ACVP

## IMAGING PERFORMED BY

Dr. Karen Ebersole  
DVM, DABVP

## HOSPITAL NAME

Scanvet

## REFERRING VET

Dr. Balboni

## INVOICE

69355

## DATE

12/16/25

**The information and recommendations provided are based on the images presented by the referring veterinarian/sonographer. No evaluation can be communicated regarding pathology that was not visible in the image/video clips provided.**

Thank you for this referral. If the clinical or image interpretation does not parallel your findings or if I can be of any further assistance please contact me.

**L.D. McGill, DVM, Ph.D., DACVP**

8288 Top of the World Dr. Cottonwood Heights, UT 84121

Cell: 801-865-1220 [Ldmcgill.vetpath@gmail.com](mailto:Ldmcgill.vetpath@gmail.com)