



PATIENT

Piper Ryan

SPECIES

Canine

BREED

Flat Coat Retriever

SEX

Spayed female

AGE

8 years

WEIGHT

75 lbs

INTERPRETED BY

Dr. Lawrence McGill,
DVM,Ph.D.,Diplomate,
ACVP

IMAGING PERFORMED BY

Dr. Lawrence McGill,
DVM Ph.D, Diplomate

HOSPITAL NAME

Central VH

REFERRING VET

Dr. Anna St Sir

INVOICE

69309

DATE

12/15/25

PRESENTING CLINICAL SIGNS

History: Slightly raised, hairless dermal mass (1cm diameter) caudal left thigh.

CYTOLOGY SUBMISSION

FNA of the skin mass was obtained

OBSERVATIONS

Skin mass: Submitted are 2 excellent videos of moderate to excellent collections of cells from the skin mass on Piper. The cellularity is rather consistent with rounded to elongated nuclei and light-colored cytoplasm. The cells are piling upon each other. There is minimal anisokaryosis. Nucleoli are not identified.

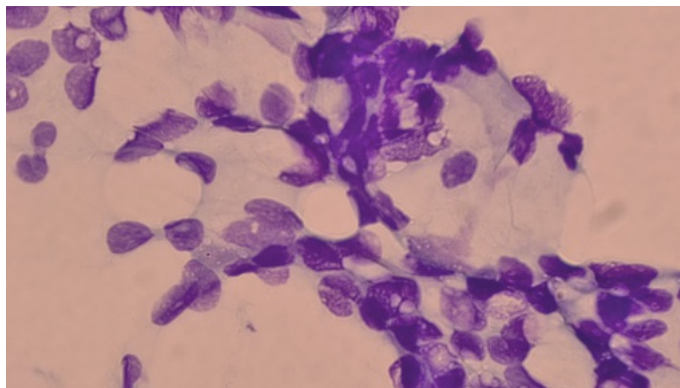
INTERPRETATION OF FINDINGS & FURTHER RECOMMENDATIONS

Skin mass - Proliferative cells suggesting potential basal cell tumor or possible low-grade sarcoma.

COMMENTS

This is a proliferative process demonstrating changes that appear to be benign or low grade. Some of the fields suggest a possibility of epithelial cells such as a basal cell tumor but other fields suggest the possibility of a low-grade sarcoma. In either instance, this growth needs to be excised. It appears to be benign in these locations and I would hope for a favorable prognosis with complete excision.

CYTOLOGY IMAGE



This is an image of the proliferative cells collected from the skin lesion on Piper. Some of the cells suggest spindle cell proliferation whereas others suggest the possibility of a low-grade epithelial proliferation such as a basal cell tumor.

The information and recommendations provided are based on the images presented by the referring veterinarian/sonographer. No evaluation can be communicated regarding pathology that was not visible in the image/video clips provided.



PATIENT

Piper Ryan

SPECIES

Canine

BREED

Flat Coat Retriever

SEX

Spayed female

AGE

8 years

WEIGHT

75 lbs

INTERPRETED BY

Dr. Lawrence McGill,
DVM,Ph.D.,Diplomate,
ACVP

IMAGING PERFORMED BY

Dr. Lawrence McGill,
DVM Ph.D, Diplomate

HOSPITAL NAME

Central VH

REFERRING VET

Dr. Anna St Sir

INVOICE

69309

DATE

12/15/25

Thank you for this referral. If the clinical or image interpretation does not parallel your findings or if I can be of any further assistance please contact me.

L.D. McGill, DVM, Ph.D., DACVP

8288 Top of the World Dr. Cottonwood Heights, UT 84121

Cell: 801-865-1220 Ldmcgill.vetpath@gmail.com