

PATIENT

Ringo Showa

SPECIES

Canine

BREED

Beagle

SEX

Male

AGE

5 Years

WEIGHT

15 kg

INTERPRETED BY

Dr. Lawrence McGill,
DVM,Ph.D.,Diplomate,
ACVP

IMAGING PERFORMED BY

Dr. Khaled Ashour

HOSPITAL NAME

The Pet Vet Dubai

REFERRING VET

Dr. Khaled Ashour

INVOICE

35457

DATE

11/9/25

PRESENTING CLINICAL SIGNS

History: Recurrent oozing open wounds around the neck and elbows, & hocks tested negative for leishmania PCR from blood and skin biopsy - the dog is on cytopoint, amoxyclav and chlorehexidine shampoo.

CYTOLOGY SUBMISSION

FNA of skin lesion

OBSERVATIONS

Submitted are 4 very good images and an excellent video of cells collected from the inflamed neck mass on Ringo. I was unable to identify any yeast or fungal elements but there are aggregates of bacterial organisms throughout the collection. Most of these appear to be coccoid bacteria. The majority of the cellularity consists of neutrophils with macrophages and necrotic cells. There are no suggestions of malignant characteristics in the collection.

INTERPRETATION OF FINDINGS & FURTHER RECOMMENDATIONS

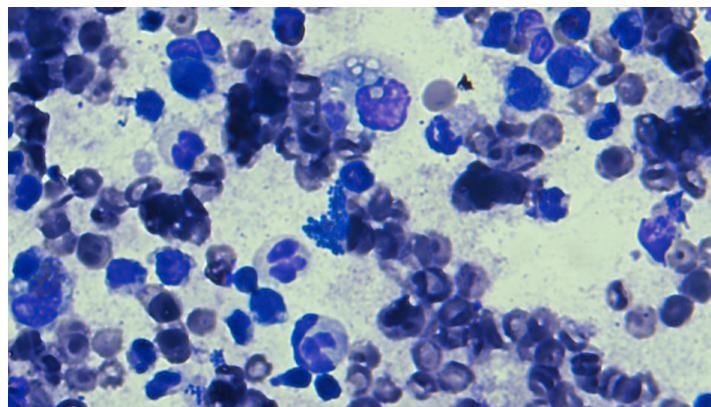
Skin lesion - Pyogranulomatous inflammation with necrosis and bacterial infection.

COMMENTS

I was unable to identify any fungal agents or suggestions of yeast organisms. There were suggestions of bacterial organisms in several cells and bacterial colonies. Most of these colonies were coccoid bacteria. I wondered about the possibility of methicillin resistant bacteria. Culture may be beneficial to identify a specific bacteria in this case. A guarded prognosis is warranted due to the chronicity and severe inflammation in this instance.

CYTOLOGY IMAGE

This image demonstrates a mixture of inflammatory cells with macrophages, neutrophils and degenerate cells and scattered aggregates of apparent coccoid bacteria collected from the skin lesion on Ringo.



The information and recommendations provided are based on the images presented by the



PATIENT

Ringo Showa

SPECIES

Canine

BREED

Beagle

SEX

Male

AGE

5 Years

WEIGHT

15 kg

INTERPRETED BY

Dr. Lawrence McGill,
DVM, Ph.D., Diplomate,
ACVP

IMAGING PERFORMED BY

Dr. Khaled Ashour

HOSPITAL NAME

The Pet Vet Dubai

REFERRING VET

Dr. Khaled Ashour

INVOICE

35457

DATE

11/9/25

referring veterinarian/sonographer. No evaluation can be communicated regarding pathology that was not visible in the image/video clips provided.

Thank you for this referral. If the clinical or image interpretation does not parallel your findings or if I can be of any further assistance please contact me.

L.D. McGill, DVM, Ph.D., DACVP

8288 Top of the World Dr. Cottonwood Heights, UT 84121

Cell: 801-865-1220 Ldmcgill.vetpath@gmail.com