



PATIENT

Lucy Zakour

SPECIES

Feline

BREED

DSH

SEX

Female

AGE

14 Years

WEIGHT

2.7

INTERPRETED BY

Dr. Lawrence McGill,
DVM,Ph.D.,Diplomate,
ACVP

IMAGING PERFORMED BY

Dr. Islam Khalifa

HOSPITAL NAME

The Pet Vet Dubai

REFERRING VET

Dr. Islam Khalifa

INVOICE

35456

DATE

11/9/25

PRESENTING CLINICAL SIGNS

History: Historic constipation presented with abdominal effusion of unknown source. Ultrasound main findings are free fluid (anechoic) with hypoechoic parenchyma of pancreas surrounded with severe hyperechoic reactive mesenteric fat that appeared totally abnormal (same appearance of carcinomatosis), cat has abnormal fpli. Fluid of TP 0.9 and Serosanguinous fluid. Abnormal PE/Chem/CBC/UA Results: Low HCT, and other comprehensive blood test was unremarkable .NO R-CHF OR L-CHF and chest is clear.

CYTOLOGY SUBMISSION

FNA of the pancreas

OBSERVATIONS

Submitted are 8 excellent images and one excellent video of excellent collections of cells from this lesion on the pancreas. There are multiple aggregates of cells that have an epithelial pattern of aggregation with prominent anisocytosis and anisokaryosis. There is a marked increase in inflammatory cells surrounding these packets of cells. The inflammatory cells include neutrophils and large numbers of macrophages that have irregular cytoplasm that is granulated and vacuolated. Some of these cells are associated with the packets and suggest cells that are sloughing off of the aggregated cellularity.

INTERPRETATION OF FINDINGS & FURTHER RECOMMENDATIONS

Pancreas - Packets of cells suggestive of carcinoma with extensive pyogranulomatous inflammation.

COMMENTS

The multiple aggregates of cells suggest the likelihood of a carcinoma but it is associated with extensive inflammation which includes massive numbers of macrophages and neutrophils. A few of the cells that have some similarity to macrophages could be similar epithelial cells to those in the packets of cells collected. There is extensive inflammation. Exploratory and excision of the mass will be required to confirm the process. There is definitely severe inflammation at this time.

CYTOLOGY IMAGE

This image demonstrates a group of cells that have the appearance of pancreatic acinar carcinoma cells. There may even be a mitotic figure in the lower right. Surrounding these aggregates of cells there are large numbers of neutrophils and macrophages collected from Lucy.



PATIENT

Lucy Zakour

SPECIES

Feline

BREED

DSH

SEX

Female

AGE

14 Years

WEIGHT

2.7

INTERPRETED BY

Dr. Lawrence McGill,
DVM, Ph.D., Diplomate,
ACVP

IMAGING PERFORMED BY

Dr. Islam Khalifa

HOSPITAL NAME

The Pet Vet Dubai

REFERRING VET

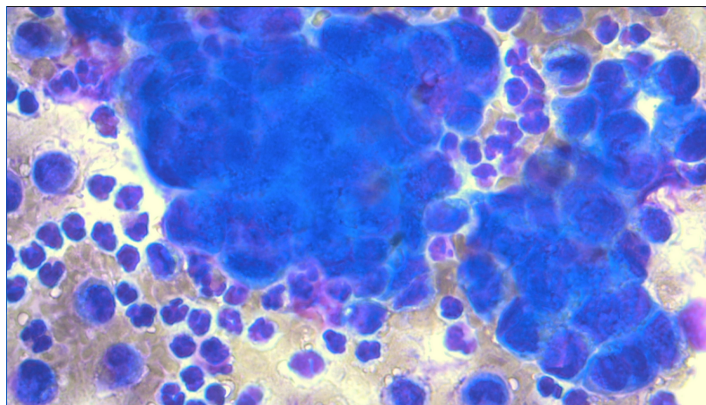
Dr. Islam Khalifa

INVOICE

35456

DATE

11/9/25



The information and recommendations provided are based on the images presented by the referring veterinarian/sonographer. No evaluation can be communicated regarding pathology that was not visible in the image/video clips provided.

Thank you for this referral. If the clinical or image interpretation does not parallel your findings or if I can be of any further assistance please contact me.

L.D. McGill, DVM, Ph.D., DACVP

8288 Top of the World Dr. Cottonwood Heights, UT 84121

Cell: 801-865-1220 Ldmcgill.vetpath@gmail.com