



## PATIENT

Harry Cielo

## SPECIES

Feline

## BREED

Domestic Shorthair

## SEX

Neutered male

## AGE

3 years

## WEIGHT

7.7 kg

## INTERPRETED BY

Dr. Lawrence McGill,  
DVM, Ph.D., Diplomate,  
ACVP

## IMAGING PERFORMED BY

Dr. Iftikhar Raza

## HOSPITAL NAME

Pawsitive Veterinary  
Clinic Dubai Silicon  
Oasis

## REFERRING VET

Dr. Iftikhar Raza

## INVOICE

69091

## DATE

11/26/25

## PRESENTING CLINICAL SIGNS

History: 3 year old male neutered domestic short hair cat presented with acute onset of dyspnea, survey radiographs of chest showed pleural effusions and ultrasound examination of thoracic cavity revealed copious amount of pleural effusions along with mass present next to heart, fine needle aspiration was performed and is submitted for evaluation

## CYTOLOGY SUBMISSION

Thoracic FNA was submitted

## OBSERVATIONS

Thoracic aspirate: Submitted are 57 very good images of excellent to moderate collections of cells from the thoracic mass and fluid in Harry. The cellularity has a background of red blood cells but the majority of the cells are round cells. Many of the round cells are small lymphoid cells but there are many large lymphoid cells with scattered mitotic figures and necrotic cells. Rare neutrophils are identified.

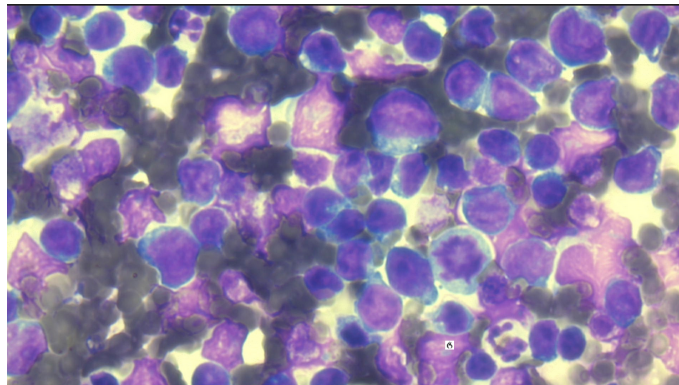
## INTERPRETATION OF FINDINGS & FURTHER RECOMMENDATIONS

Thoracic aspirate - Lymphoma suggestive of mediastinal lymphoma or possible thymoma.

## COMMENTS

The cellularity on this collection is characteristic of a lymphoid proliferative process which may either be mediastinal lymphoma or a thymoma. This is definitely showing characteristics cellularity-wise of a lymphoma. There are adequate numbers of lymphoid cells on these slides to submit for PARR testing if desired. Some of the collection may be from fluid or mediastinal tissue. There was some fat tissue which is secondary and not primary. There is mild degeneration of some of the cells. An unfavorable prognosis is warranted in my opinion but chemotherapy may prolong life in Harry.

## CYTOLOGY IMAGE



This is an image of cells collected from the thoracic region in Harry. Note the large lymphoid cells are more numerous and there is a mitotic figure in this field.



## PATIENT

Harry Cielo

## SPECIES

Feline

## BREED

Domestic Shorthair

## SEX

Neutered male

## AGE

3 years

## WEIGHT

7.7 kg

## INTERPRETED BY

Dr. Lawrence McGill,  
DVM, Ph.D., Diplomate,  
ACVP

## IMAGING PERFORMED BY

Dr. Iftikhar Raza

## HOSPITAL NAME

Pawsitive Veterinary  
Clinic Dubai Silicon  
Oasis

## REFERRING VET

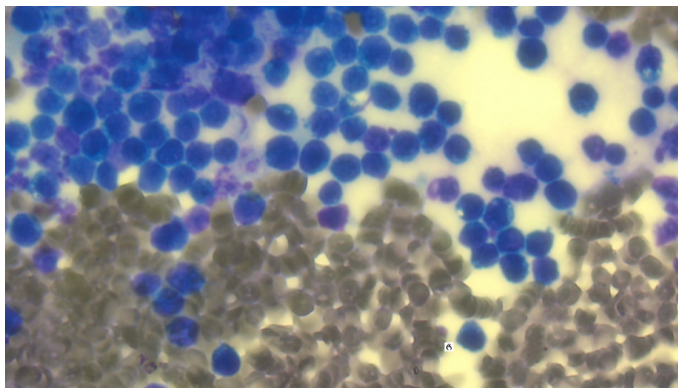
Dr. Iftikhar Raza

## INVOICE

69091

## DATE

11/26/25



This is an image of lymphoid cells associated with large numbers of RBCs collected from the thoracic region in Harry. This image shows the massive numbers of lymphoid cells in many of the fields.

**The information and recommendations provided are based on the images presented by the referring veterinarian/sonographer. No evaluation can be communicated regarding pathology that was not visible in the image/video clips provided.**

Thank you for this referral. If the clinical or image interpretation does not parallel your findings or if I can be of any further assistance please contact me.

**L.D. McGill, DVM, Ph.D., DACVP**

8288 Top of the World Dr. Cottonwood Heights, UT 84121

Cell: 801-865-1220 [Ldmcgill.vetpath@gmail.com](mailto:Ldmcgill.vetpath@gmail.com)