



PATIENT

Merlin Lipinski

SPECIES

Feline

BREED

Domestic Longhair

SEX

Neutered male

AGE

8 years

WEIGHT

10.6 lbs

INTERPRETED BY

Dr. Lawrence McGill,
DVM,Ph.D.,Diplomate,
ACVP

IMAGING PERFORMED BY

Karen Ebersole DVM,
DABVP (Canine/Feline)

HOSPITAL NAME

Scanvet

REFERRING VET

Dr. Chadbourne

INVOICE

68967

DATE

11/24/25

PRESENTING CLINICAL SIGNS

History: 2-3 month history of progressive vomiting, diarrhea, and weight loss. Full sedation needed for full physical exam. USG FNA of gastric mural mass.

PE: oral exam - NSF, minimal tartar or inflammation. BCS 3/9 with muscle wasting. Hct 36%, mild monocytosis, and low total protein (6.0) with normal Alb and Glob. AUS - Gastric mural mass in body of stomach and pyloric outflow. Complete loss of layering, hypoechoic and highly vascular. Regional mesenteric inflammation and lymphadenopathy. Delayed gastric emptying.

CYTOLOGY SUBMISSION

FNA of gastric mass was submitted.

OBSERVATIONS

Gastric mass: Submitted are 4 excellent videos of excellent collections of cells from the gastric mass in Merlin. The cellularity consists of a mixed population of cells with large numbers of round cells. Many of the round cells are small to intermediate lymphoid cells with large lymphoid cells present as well. There are scattered neutrophils throughout the collection with rare macrophages. The majority of the cells are lymphoid cells.

INTERPRETATION OF FINDINGS & FURTHER RECOMMENDATIONS

Gastric mass - Increased numbers of lymphoid cells strongly suggestive of gastric lymphoma.

COMMENTS

The cellularity in this collection strongly suggests early gastric lymphoma with secondary chronic inflammation. The changes are not classic for a primary inflammatory process nor to identify any other changes that would support a cause for inflammation. Malignancy such as a lymphoma seems to be the most likely diagnosis. Continued evaluation for that neoplastic process is encouraged. If problems continue, then follow-up gastric biopsies will be required to confirm the diagnosis. Other tissues may be involved in this lymphoma process in Merlin. A guarded to unfavorable prognosis is warranted due to the cellularity identified in these videos.



PATIENT

Merlin Lipinski

SPECIES

Feline

BREED

Domestic Longhair

SEX

Neutered male

AGE

8 years

WEIGHT

10.6 lbs

INTERPRETED BY

Dr. Lawrence McGill,
DVM, Ph.D., Diplomate,
ACVP

IMAGING PERFORMED BY

Karen Ebersole DVM,
DABVP (Canine/Feline)

HOSPITAL NAME

Scanvet

REFERRING VET

Dr. Chadbourne

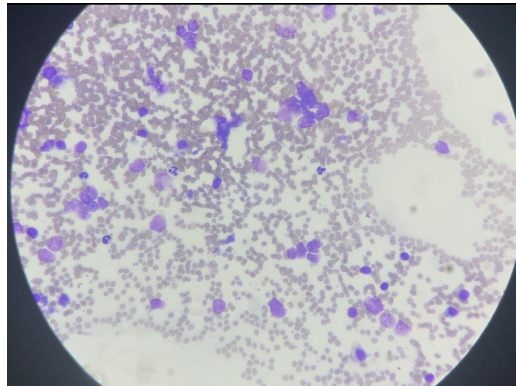
INVOICE

68967

DATE

11/24/25

CYTOLOGY IMAGE



This image demonstrates a field with large numbers of lymphoid cells and scattered neutrophils collected from the gastric wall mass in Merlin. Note the irregular lymphoid cells and large numbers of lymphoid cells in this collection.

The information and recommendations provided are based on the images presented by the referring veterinarian/sonographer. No evaluation can be communicated regarding pathology that was not visible in the image/video clips provided.

Thank you for this referral. If the clinical or image interpretation does not parallel your findings or if I can be of any further assistance please contact me.

L.D. McGill, DVM, Ph.D., DACVP

8288 Top of the World Dr. Cottonwood Heights, UT 84121

Cell: 801-865-1220 Ldmcgill.vetpath@gmail.com