



PATIENT

Roxy Davidson

SPECIES

Canine

BREED

Shepherd Mix

SEX

Spayed Female

AGE

5 Years

WEIGHT

70

INTERPRETED BY

Dr. Lawrence McGill,
DVM,Ph.D.,Diplomate,
ACVP

IMAGING PERFORMED BY

Waffle

HOSPITAL NAME

Torch Lake VC

REFERRING VET

Dr. Waffle

INVOICE

35581

DATE

11/22/25

PRESENTING CLINICAL SIGNS

History of swelling at lateral aspect of carpus Hx of addisons.

CYTOLOGY SUBMISSION

FNA of the lateral carpus.

OBSERVATIONS

Submitted are 5 good images that are slightly out of focus of cells collected from the lateral carpal mass on Roxy. The cellularity is consistent throughout the images. The cells are polyhedral to elongated cells some of which have tails. The nuclei are open faced with prominent nucleoli. There is prominent cytoplasm. The cellularity is minimal but adequate to suggest a proliferative process.

INTERPRETATION OF FINDINGS & FURTHER RECOMMENDATIOINS

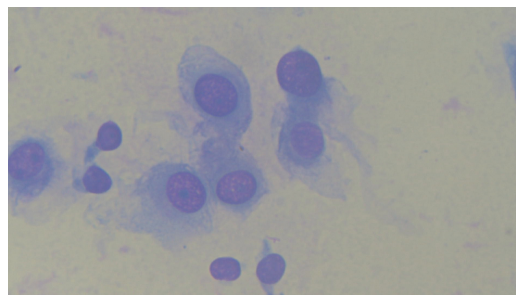
Lateral carpal mass - Spindloid to polyhedral cells suggesting soft tissue sarcoma.

COMMENTS

The cellularity is minimal in these five images. Soft tissue sarcomas particularly further down the leg can be difficult to aspirate because the cells do not want to release from the collagenous mass. This cellularity strongly suggests a soft tissue sarcoma, probably tendon sheath in origin. These growths can be difficult to completely excise. Following excision, many of these growths will recur due to the fact that tumor cells are infiltrating in and around tendons and nerves and vessels in this region. Metastasis is extremely rare. A guarded prognosis is warranted due to the potential of recurrence and not due to metastasis.

CYTOLOGY IMAGE

This is an image representing the cells collected from the lateral carpal mass on Roxy. Note the polyhedral to elongated cells and one or two the cells have tails.



The information and recommendations provided are based on the images presented by the referring veterinarian/sonographer. No evaluation can be communicated regarding pathology that was not visible in the image/video clips provided.

Thank you for this referral. If the clinical or image interpretation does not parallel your findings or if I can be of any further assistance please contact me.



PATIENT

L.D. McGill, DVM, Ph.D., DACVP

Roxy Davidson

8288 Top of the World Dr. Cottonwood Heights, UT 84121

SPECIES

Cell: 801-865-1220 Ldmcgill.vetpath@gmail.com

Canine

BREED

Shepherd Mix

SEX

Spayed Female

AGE

5 Years

WEIGHT

70

INTERPRETED BY

Dr. Lawrence McGill,
DVM, Ph.D., Diplomate,
ACVP

**IMAGING
PERFORMED BY**

Waffle

HOSPITAL NAME

Torch Lake VC

REFERRING VET

Dr. Waffle

INVOICE

35581

DATE

11/22/25