



PATIENT

Bitsy Benjamin

SPECIES

Feline

BREED

DSH

SEX

Spayed Female

AGE

11 Years 6 Months

WEIGHT

9 lbs

INTERPRETED BY

Dr. Lawrence McGill,
DVM,Ph.D.,Diplomate,
ACVP

IMAGING PERFORMED BY

Rebecca Hamilton

HOSPITAL NAME

Morris Hills Veterinary
Clinic

REFERRING VET

Dr. Hirshenson

INVOICE

72044

DATE

11/21/25

PRESENTING CLINICAL SIGNS

Owner reports that cat will pass blood in stools also abd. palpation susp. of mass effect. Miralax daily. FNA Distal Colon mass effect.

CYTOLOGY SUBMISSION

Intestinal mass.

OBSERVATIONS

Submitted are 9 excellent videos of cells collected from the intestinal aspiration in Bitsy. The cellularity is consistent through all of the videos which includes large numbers of round cells. Many of the round cells are slightly elongated which is due to smearing. There are rare neutrophils. The majority of the cells have the appearance of lymphoid cells that are irregular. Some degenerate cells are scattered throughout the collection. This cellularity is very uniform throughout these collections.

INTERPRETATION OF FINDINGS & FURTHER RECOMMENDATIONS

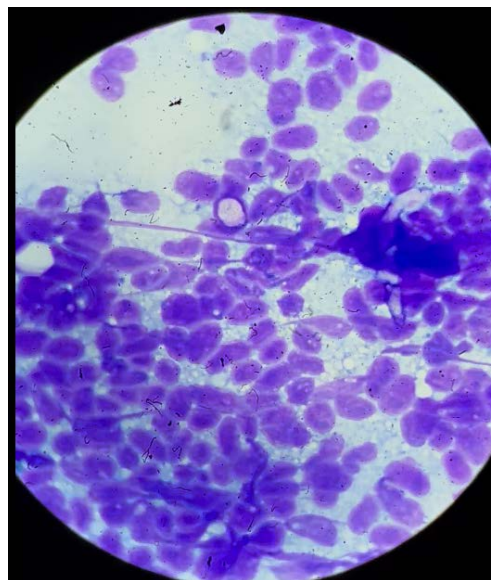
Large numbers of small to intermediate lymphoid cells consistent with intestinal lymphoma.

COMMENTS

The cellularity in this collection is extremely uniform suggesting the likelihood of lymphoma. This is particularly suggested since there are so many round cells throughout the collection. The round cells are elongated but there is degeneration and inflammation with those cells but it is minimal. This strongly supports a small to intermediate round cell lymphoma. Wide excision of the massive possible may be beneficial in prolonging life in Bitsy. Without therapy, an unfavorable prognosis is warranted.

CYTOLOGY IMAGE

This image demonstrates large numbers of round cells with irregular nuclei that are collected from the intestinal mass in Bitsy. Note the large number of round cells with irregular nuclei in this collection.





PATIENT

Bitsy Benjamin

SPECIES

Feline

BREED

DSH

SEX

Spayed Female

AGE

11 Years 6 Months

WEIGHT

9 lbs

INTERPRETED BY

Dr. Lawrence McGill,
DVM, Ph.D., Diplomate,
ACVP

**IMAGING
PERFORMED BY**

Rebecca Hamilton

HOSPITAL NAME

Morris Hills Veterinary
Clinic

REFERRING VET

Dr. Hirshenson

INVOICE

72044

DATE

11/21/25

The information and recommendations provided are based on the images presented by the referring veterinarian/sonographer. No evaluation can be communicated regarding pathology that was not visible in the image/video clips provided.

Thank you for this referral. If the clinical or image interpretation does not parallel your findings or if I can be of any further assistance please contact me.

L.D. McGill, DVM, Ph.D., DACVP

8288 Top of the World Dr. Cottonwood Heights, UT 84121

Cell: 801-865-1220 Ldmcgill.vetpath@gmail.com