



PATIENT

Cookie Mc 119071

SPECIES

Canine

BREED

Toy Poodle

SEX

Female

AGE

1 year

WEIGHT

3 kg

INTERPRETED BY

Dr. Lawrence McGill,
DVM,Ph.D.,Diplomate,
ACVP

IMAGING PERFORMED BY

Dr. Junaid

HOSPITAL NAME

Pawsitive Veterinary
Clinic Dubai Silicon
Oasis

REFERRING VET

Dr. Junaid

INVOICE

68591

DATE

11/12/25

PRESENTING CLINICAL SIGNS

History: 1yr old Poodle female presented with crusty, depigmented, symmetrical and non-itchy patch/lesion on nasal planum. No evidence of mites upon skin scraping. Impression smear was observed at 100X under microscope.

CYTOLOGY SUBMISSION

FNA of the skin lesion

OBSERVATIONS

Skin lesion: Submitted are 10 excellent images of the lesion and cells collected from the surface of the lesion with an impression smear on Cookie. The cellularity is mixed. There are large numbers of neutrophils, some of which are degenerate. There are good numbers of macrophages that have prominent cytoplasm. Scattered lymphocytes are identified. There are no changes suggesting malignant characteristics.

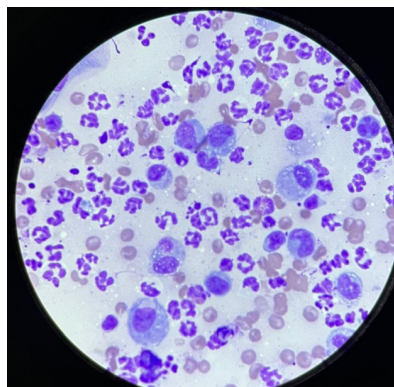
INTERPRETATION OF FINDINGS & FURTHER RECOMMENDATIONS

Skin lesion - Pyogranulomatous inflammation with possible bacterial infection.

COMMENTS

This collection is chronic inflammatory cellularity and could be from many different conditions. This is likely a secondary change and not primary. Fine needle aspiration of the deeper tissue may have been beneficial. The lesion could be any kind of inflamed skin process or possibly even some type of papilloma with secondary inflammation. Again there are no changes in this collection of images to suggest neoplasia. A guarded prognosis is warranted since the deep cellular tissue has not been evaluated. Excision and a follow-up biopsy may be necessary to confirm the process.

CYTOLOGY IMAGE



This is a representative image demonstrating a large number of neutrophils with interspersed macrophages and rare lymphocytes collected from the surface of the skin lesion on Cookie. This cellularity is likely secondary to what is occurring deep in the tissue.



PATIENT

Cookie Mc 119071

SPECIES

Canine

BREED

Toy Poodle

SEX

Female

AGE

1 year

WEIGHT

3 kg

INTERPRETED BY

Dr. Lawrence McGill,
DVM,Ph.D.,Diplomate,
ACVP

IMAGING PERFORMED BY

Dr. Junaid

HOSPITAL NAME

Pawsitive Veterinary
Clinic Dubai Silicon
Oasis

REFERRING VET

Dr. Junaid

INVOICE

68591

DATE

11/12/25

The information and recommendations provided are based on the images presented by the referring veterinarian/sonographer. No evaluation can be communicated regarding pathology that was not visible in the image/video clips provided.

Thank you for this referral. If the clinical or image interpretation does not parallel your findings or if I can be of any further assistance please contact me.

L.D. McGill, DVM, Ph.D., DACVP

8288 Top of the World Dr. Cottonwood Heights, UT 84121

Cell: 801-865-1220 Ldmcgill.vetpath@gmail.com