



PATIENT

Churro Kitten Angels

SPECIES

Feline

BREED

Domestic Longhair

SEX

Female

AGE

4 months

WEIGHT

4.3 lbs

INTERPRETED BY

Dr. Lawrence McGill,
DVM,Ph.D.,Diplomate,
ACVP

IMAGING PERFORMED BY

Nick Pizzemento

HOSPITAL NAME

Central VH

REFERRING VET

Dr. Anna St Sir

INVOICE

68536

DATE

11/10/25

PRESENTING CLINICAL SIGNS

History: Chronic diarrhea, FNA taken from mesenteric LN

CYTOLOGY SUBMISSION

FNA of the mesenteric lymph node was submitted

OBSERVATIONS

Lymph node: Submitted are 9 excellent videos of excellent collections of cells from the mesenteric lymph node in Churro. The cellularity includes large numbers of lymphoid cells the majority of which are small lymphocytes. There are intermediate lymphoid cells and scattered reactive lymphoid cells suggesting reactivity of the lymphoid tissue. Scattered neutrophils and rare eosinophils are identified. Rare macrophages were visualized.

INTERPRETATION OF FINDINGS & FURTHER RECOMMENDATIONS

Mesenteric lymph node - Mild chronic suppurative lymphadenitis with reactive or stimulated lymph node.

COMMENTS

The cellularity in this collection supports chronic inflammatory lymphadenitis. This easily could be the result of an inflammatory bowel disease or possibly FIP. There is some information recently that suggests that diarrhea with chronic inflammation in the cat can be the result of FIP. Further evaluation for coronavirus infection in Churro is encouraged. Bacterial culture of a rectal swab may be beneficial as well. There is no suggestion of malignancy in this collection but there is certainly chronic inflammation. A few eosinophils are present which could suggest an allergic process but all of these changes are secondary. If bacterial culture has not been undertaken, then that would be suggested although I would expect to see more neutrophils in the lymph node than observed with bacterial infection. I am more suspicious of chronic inflammation of an inflammatory bowel type or possibly FIP as the underlying process. A guarded prognosis is warranted since there is inflammation and chronic reaction in the lymph node.



PATIENT

Churro Kitten Angels

SPECIES

Feline

BREED

Domestic Longhair

SEX

Female

AGE

4 months

WEIGHT

4.3 lbs

INTERPRETED BY

Dr. Lawrence McGill,
DVM, Ph.D., Diplomate,
ACVP

IMAGING PERFORMED BY

Nick Pizzemento

HOSPITAL NAME

Central VH

REFERRING VET

Dr. Anna St Sir

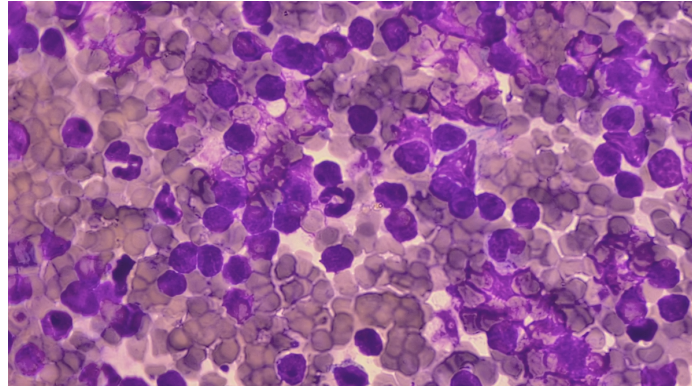
INVOICE

68536

DATE

11/10/25

CYTOLOGY IMAGE



This is a representative image demonstrating large numbers of small lymphocytes with scattered reactive lymphoid cells and intermediate cells and a neutrophil and eosinophil in the collection from the mesenteric lymph node in Churro.

The information and recommendations provided are based on the images presented by the referring veterinarian/sonographer. No evaluation can be communicated regarding pathology that was not visible in the image/video clips provided.

Thank you for this referral. If the clinical or image interpretation does not parallel your findings or if I can be of any further assistance please contact me.

L.D. McGill, DVM, Ph.D., DACVP

8288 Top of the World Dr. Cottonwood Heights, UT 84121

Cell: 801-865-1220 Ldmcgill.vetpath@gmail.com