



PATIENT

Luke Henrieta

SPECIES

Canine

BREED

Rhodesian Ridgeback

SEX

Male

AGE

7 years

WEIGHT

46 lbs

INTERPRETED BY

Dr. Lawrence McGill,
DVM, Ph.D., Diplomate,
ACVP

IMAGING PERFORMED BY

Dr. Saddam Hussain

HOSPITAL NAME

Pawsitive Veterinary
Clinic Dubai Silicon
Oasis

REFERRING VET

Dr. Waseem

INVOICE

69949

DATE

1/9/26

PRESENTING CLINICAL SIGNS

History: Luke with a previous history of skin allergies presented with a single, localized focal lump over the left shoulder, first noticed approximately 2 months ago. The mass is solid, non-painful on palpation, not increasing in size non-pruritic, and shows no signs of fluctuation or fluid accumulation, with no similar lesions detected elsewhere on the body. FNA performed for further evaluation

CYTOLOGY SUBMISSION

FNA of skin mass was submitted

OBSERVATIONS

Skin mass: Submitted are 21 very good images of minimal numbers of cells collected from the skin mass on Luke. The cellularity is mixed. The majority of the background is necrotic debris and lipid. Interspersed are scattered neutrophils, macrophages and keratinized cells. Malignant cellularity is not identified. The cellularity is most consistent with a chronic inflammatory localized process.

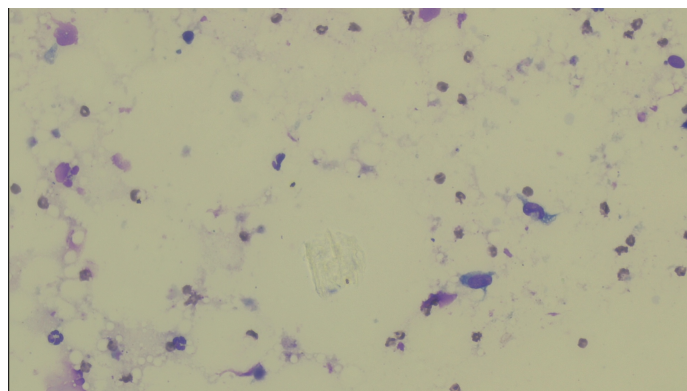
INTERPRETATION OF FINDINGS & FURTHER RECOMMENDATIONS

Skin mass - Mild pyogranulomatous inflammation with necrosis and keratinized debris.

COMMENTS

The cellularity supports a chronic inflammatory process. With the keratinized debris, the likelihood of a ruptured keratinized cyst is most prominent. These lesions will result in necrosis and inflammation and fat tissue response. These are benign inflammatory processes but the mass will not go away without excision. Anti-inflammatory therapy can be attempted but I would not expect it to disappear. Surgical excision is encouraged due to the fact that these reactions can continue to enlarge since keratinized material is extremely irritating. A good if completely excised prognosis is warranted with this mass.

CYTOLOGY IMAGE



This is an image representing the mixed cell collection of macrophages and neutrophils with degenerate debris and keratinized cells in the center collected from the skin mass on Luke.



PATIENT

Luke Henrieta

SPECIES

Canine

BREED

Rhodesian Ridgeback

SEX

Male

AGE

7 years

WEIGHT

46 lbs

INTERPRETED BY

Dr. Lawrence McGill,
DVM, Ph.D., Diplomate,
ACVP

IMAGING PERFORMED BY

Dr. Saddam Hussain

HOSPITAL NAME

Pawsitive Veterinary
Clinic Dubai Silicon
Oasis

REFERRING VET

Dr. Waseem

INVOICE

69949

DATE

1/9/26

The information and recommendations provided are based on the images presented by the referring veterinarian/sonographer. No evaluation can be communicated regarding pathology that was not visible in the image/video clips provided.

Thank you for this referral. If the clinical or image interpretation does not parallel your findings or if I can be of any further assistance please contact me.

L.D. McGill, DVM, Ph.D., DACVP

8288 Top of the World Dr. Cottonwood Heights, UT 84121

Cell: 801-865-1220 Ldmcgill.vetpath@gmail.com